

Rare case of intragastric primary malignant melanoma

Dr.R.Nagamani*, Dr.S.Manohar**, Dr.Manasa**

* Department of Medicine,Osmania general hospital

** Department of Medicine, Osmania general hospital

Abstract- Malignant melanoma is the leading cause of death due to skin disease. Malignant melanoma is known to metastasize to different organs of the human body with an unusual predilection for the gastrointestinal tract. Gastrointestinal invasion is a rare condition and is often associated with the invasion of other visceral organs.

Index Terms-Gastric melanoma, Metastasis,

I. INTRODUCTION

Primary intestinal melanoma is difficult to differentiate from metastatic melanoma, especially given that the primary cutaneous lesion has the potential to regress and disappear. In addition, melanoma by itself is a great mimicker of other neoplastic conditions and may create a major diagnostic challenge when presenting at an intrabdominal location. The mean survival time of these patients is consistently less than one year. The exact clinical incidence of gastrointestinal melanoma cannot be determined from any large series, but the stomach, after the small bowel, is the second most common site involved. Tumour thickness is the single most important prognostic factor.

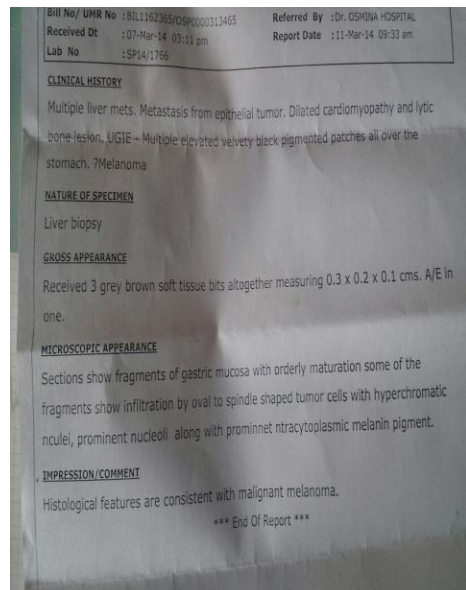
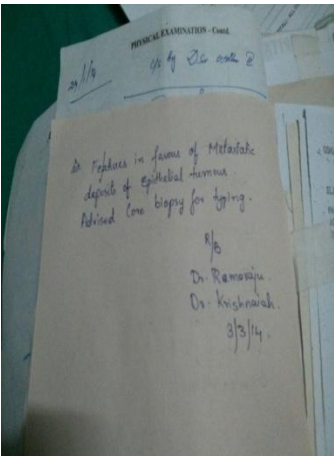
CASE STUDY

- ❖ 60 yrs old female patient came with the complaints of low grade fever – 1yr
Shortness of breath – 1yr
Loss of appetite – 3months
Loss of weight – 3 months
Generalised weakness – 3 months
Abdominal distension – 20 days
Edema of feet – 20 days
- ❖ No h/o fever, cough, chest pain, vomitings, loose motions, oliguria, bleeding manifestations at present.
- ❖ Past history : no h/o similar complaints in the past
- ❖ Operated for haemorrhoids 2 yrs back
- ❖ Family history: not significant
- ❖ Personal history : mixed diet, decreased appetite, bowel & bladder regular
- ❖ General examination:
 - ❖ 60 yrs old female pt conscious, coherent
 - ❖ no pallor, icterus, cyanosis, clubbing
 - ❖ edema feet (+), lymphadenopathy (+)
 - ❖ vitals stable

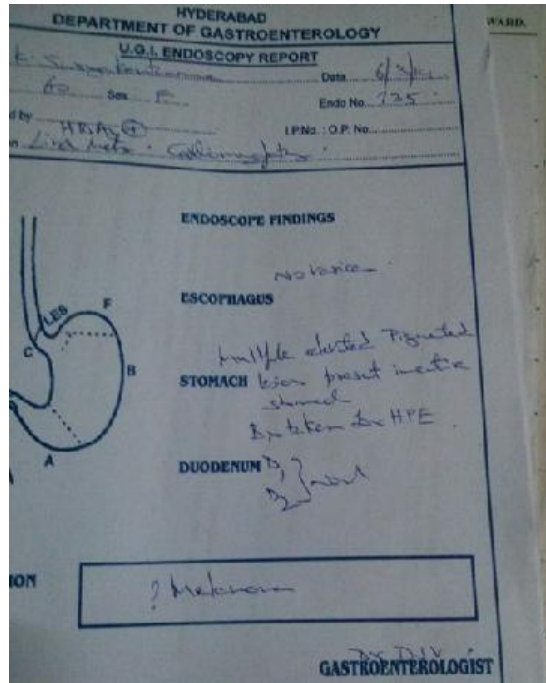
- ❖ GIT Examination:
 - Upper GIT – Normal
 - Lower GIT:
 - Abdomen is uniformly distended
 - No Organomegaly
 - Liver span –
 - Ascites present, shifting dullness (+)
- ❖ CVS Examination:
 - Cardiomegaly
 - raised JVP
- Investigations:
 - Hb: 13 gms, WBC: 7200, Platelets –adequate
 - Liver function test: Total Bilirubin- 0.9, Total Proteins – 7.2
 - PT INR – 1.1
 - Ascitic fluid: Proteins – 3.6, Cell count – 280, Adenosine deaminase(ADA) – 12, No malignant cells
 - Ultrasonography Abdomen – Cirrhosis of liver with multiple tiny hypo echoic nodules
 - 2D Echocardiography – Global hypokinesia of LV, all chambers dilated, LV & RV dysfunction.
- CT Chest & Abdomen – Cardiomegaly, mediastinal pleural collection +, multiple hyper intense lesions in both lungs basal segments and Lt upper lobe.
ill defined lesions in Lt lobe of liver
- CECT Abdomen – multiple non enhancing hypodense lesions both lobes of liver, pre rectal lymphadenopathy +, irregular lytic lesions in lumbar vertebra
- FNAC(Fine needle aspiration cytology) of Liver – Metastatic deposits of Epithelial tumour
- Upper GI endoscopy(UGIE) – multiple elevated pigmented lesions present in entire stomach (? Melanoma)
- Histopathology examination(HPE) of tissue – histological features are consistent with Malignant Melanoma



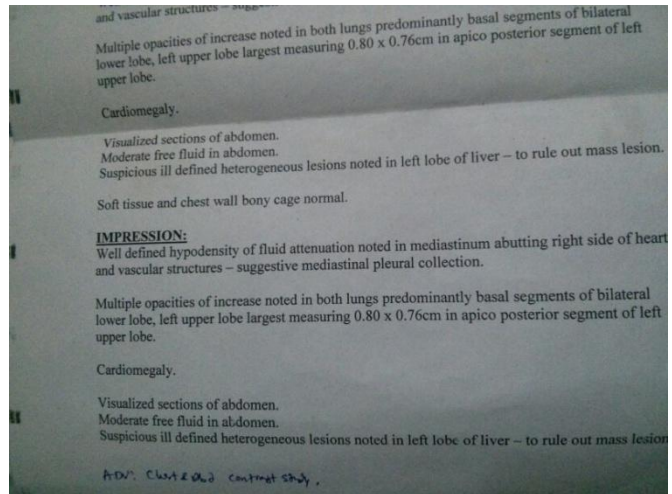
Biopsy specimen



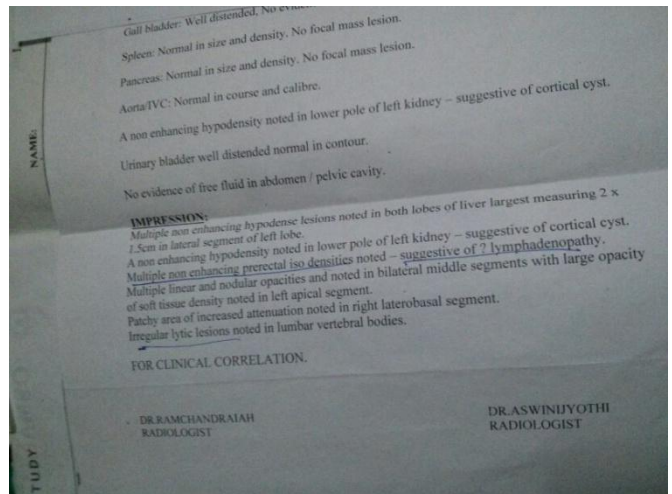
Biopsy report



UGIE



CT CHEST AND ABDOMEN



CECT ABDOMEN REPORT.

II. DISCUSSION

Melanoma accounts for 1-3% of all malignant tumours. Except cutaneous, other less common melanomas include, among others, those in gastrointestinal tract. However, their primary or secondary nature is often difficult to establish. Referring to stomach, scattered cases of primary melanoma have been reported in literature.

Autopsy frequently reveals gastrointestinal involvement in patients that have died from melanoma, however little evidence emerges in antemortem diagnosis and, even then, usually only in connection with emergency situations such as obstructions, bleeding or perforation. The frequently asymptomatic character of gastrointestinal melanoma explains why it largely eludes detection. Symptoms include mainly gastrointestinal bleeding, abdominal pain, anorexia, nausea and vomiting, weight loss, progressive dysplasia, obstruction, and occasionally acute perforation. Melena in a melanoma patient seems to be a primary symptom for gastrointestinal metastasis, even in the absence of other symptoms. In our case our patient never experienced melena. In the majority of the cases reported, the gastric involvement was a manifestation of terminal metastasis. It has been reported that almost all the areas of the human body can be affected by melanoma metastases.

Many of the previous reports on the gastric spread were based on the radiological features of the metastases. Recently, however, endoscopy has been shown to be a more reliable diagnostic tool. It permits exact morphological evaluation and direct biopsy for pathological diagnosis. Moreover, by endoscopic follow-up it is possible to monitor the course of metastases and to evaluate the results of treatment. The endoscopic classification of the gastric metastases comprises three main morphological types. Firstly there are melanotic nodules, often ulcerated at the tip, which are the most frequently observed endoscopic feature. Secondly are submucosal tumor masses, melanotic or not, which are elevated and ulcerated at the apex. This is the typical aspect of "bull's eye" lesions.

The third morphological type is mass lesions, with varying incidence of necrosis and melanosis. Additionally, gastric metastases may appear even as a simple ulcer. Concerning the anatomical site of the gastric metastases, the majority of them are reported to occur in the body and the fundus, most often at the greater curvature with lesser curvature lesions being uncommon. In our patient, the endoscopic picture of the gastric lesion showed it to be melanotic at her gastric fundus and the first part of her duodenum. The pathological evaluation could confirm the metastatic nature of the melanoma lesion. GIT metastases can appear in various morphological forms, and therefore immunohistochemistry is often useful in distinguishing between a malignant melanoma and other malignancies.

Although surgical treatment has been attempted in some

melanoma patients with gastrointestinal metastases, surgery seems to be of limited practical value and should be performed only in carefully selected patients and in patients with complications. The poor general condition of our patient by the time of the diagnosis, complicated with other organ (liver, bone and lungs) metastases, did not allow any surgical treatment.

Metastatic melanoma in various areas, from an unknown primary lesion, is well documented in the literature. The stomach, after the small bowel, is the second most common site involved. The primary origin of a melanoma in the stomach is extremely unlikely and can be accepted only if the absence of any other primary lesion is confirmed. Endoscopy has been shown to be the most reliable form of examination for the diagnosis of gastric metastases. In addition, gastric invasion is most often associated with the invasion of other organs and the mean survival time of patients presenting with a gastric metastasis is consistently less than one year. Therefore, every metastatic malignant melanoma case should undergo endoscopic examination for gastrointestinal metastases.

Current findings for our patient were assessed to indicate a malignant melanoma with metastasis to her stomach, liver, lungs and bones. Stomach metastasis due to a malignant melanoma is very rare, and such metastases are hardly ever reported among gastric metastases. This case is the first gastric and duodenal metastases observed in our clinic due to malignant melanoma. Our patient was referred to our oncology clinic after the diagnosis, for chemotherapy.

Malignant melanoma is reported to metastasize to all organs of the human body. Although it is common for it to metastasize to the gastrointestinal tract (GIT), a melanoma located primarily in the gastric mucosa is an uncommon tumor. Gastrointestinal metastases are rarely diagnosed before death, using radiological and endoscopic techniques. Also, GIT metastases can appear in various morphological forms, and therefore immunohistochemistry is often useful in distinguishing between a malignant melanoma and other malignancies.

The median survival time for melanoma patients presenting with gastrointestinal invasion is less than one year. The prolonged survival time reported in a few patients with gastrointestinal metastases is associated with aggressive surgical treatment, adjuvant chemotherapy and immunotherapy. The high mortality rate observed in these patients is associated with multiple metastases to other organs, such as lungs, liver, pancreas, spleen, endocrine glands, and brain.

Criteria for the diagnosis of primary gastric melanoma include the absence of concurrent lesions and the lack of a history of melanoma or atypical melanocytic lesion removal from the skin or other organs. Disease-free survival of at least 12 months after curative surgical excision of the involved organ has been proposed as a criterion for the distinction of a primary lesion from a metastatic lesion, as 50% of patients with stage IV

melanoma of the skin or visceral disease from an unknown primary lesion die 12 months after diagnosis.

The clinical manifestations of primary gastric melanoma are similar to those of other gastric tumors, with weight loss, upper gastrointestinal bleeding, and anemia as the most common symptoms. Most patients are asymptomatic until the tumor becomes advanced. Computed tomography scan of the abdomen, upper endoscopy, and subsequent biopsy are the main diagnostic modalities. On upper endoscopy, a mass-like lesion with black pigmentation may be seen. Immunohistochemical stains with S100 protein, Melan-A, and HMB-45 antibodies have increased the diagnostic sensitivity of biopsy and cytology and play a key role in the diagnosis of these lesions. Chemotherapy options include interferon, interleukin-12, and other agents. Prognosis is extremely poor due to the frequent delay in diagnosis, the inherently more aggressive nature of the tumor, and earlier dissemination due to the rich lymphatic and vascular supply of the gastrointestinal mucosa.

Conclusion

Malignant melanoma most commonly develops in the skin. The vast majority of gastrointestinal melanomas are metastases from a cutaneous primary tumor. In rare instances, primary malignant melanoma can arise from mucosa of the gastrointestinal tract, particularly from the esophagus, anorectum, and small bowel. Fewer than 15 cases of primary gastric melanoma have been documented in the literature.

There has been speculation in the past as to whether primary melanoma can occur in the stomach, as benign melanocytes are absent in the normal gastric wall. However, melanosis of the stomach has been well documented in the case of anal and esophageal melanoma. Thus, it is possible that primary gastric

melanoma can occur in unusual circumstances

Acknowledgment

Material from the chapter by Walter J. Urba, Carl V Washington, Hari Nadiminti from 18th edition, Harrison's principles of internal medicine.

References

- Walter J. Urba, Carl V Washington, Hari Nadiminti from 18th edition, Harrison's principles of internal medicine.
- Cutaneous squamous cell carcinoma, N Engl J Med 344:975, 2001
- Hodi FS et al: Improved survival with ipilimumab in patients with metastatic melanoma. N Engl J Med 363:711, 2010

AUTHORS

First Author – Dr. R. Nagamani, MBBS, MD (GENERAL MEDICINE), Professor of medicine, Osmania medical college and hospital, Hyderabad, Telangana, INDIA, Email- ramapantula@yahoo.com.

Second Author – Dr. S. Manohar, MBBS, MD (GENERAL MEDICINE), Professor and head of the department, Osmania medical college and hospital, Hyderabad, Telangana, INDIA

Third Author – Dr. Manasa, MBBS, Post graduate student (General medicine), Osmania medical college and hospital.

Correspondence Author – Dr. R. Nagamani, MBBS, MD (GENERAL MEDICINE), Professor of medicine, Osmania medical college and hospital, Hyderabad, Telangana, INDIA, Email- ramapantula@yahoo.com. Contact no : +919848175551.