

Case Report: Cryptococcal Meningitis as Stroke Mimic in ICL Patient

Dr. Sandeep Ghosh*, **Dr. Rohit Gupta****, **Dr. Megha Sharda*****, **Dr. Sandip Bhattacharya******, **Dr. Ashok Kumar Sharma*******

*Consultant, Department of neurology, Accord super speciality hospital

**Chairman, Department of neurology, Accord super speciality hospital

***Consultant, Department of neurology, Accord super speciality hospital

****Senior Consultant Department of Critical Care, Accord super speciality hospital

*****Consultant, Department of Critical Care, Accord super speciality hospital.

DOI: 10.29322/IJSRP.13.11.2023.p14330

<https://dx.doi.org/10.29322/IJSRP.13.11.2023.p14330>

Paper Received Date: 8th October 2023

Paper Acceptance Date: 4th November 2023

Paper Publication Date: 14th November 2023

Abstract

Background: Cryptococcal infections are frequently encountered in immunocompromised patients including patients with idiopathic CD4 T cell lymphocytopenia (ICL). They are predisposed to severe Cryptococcal infections like Cryptococcal meningoencephalitis and few may present atypically as stroke mimic.

Objective: To report a case of Cryptococcal meningoencephalitis in a patient with ICL who presented as stroke mimic.

Methods and Material: We are reporting a case of an elderly gentleman who presented with symptoms and signs of acute stroke but upon evaluation he was diagnosed as Cryptococcal meningoencephalitis and ICL.

Result: Cryptococcal meningoencephalitis may present as stroke mimic in immunocompromised patients having ICL.

Conclusion: A high index of suspicion for Cryptococcal meningoencephalitis is warranted in immunocompromised patients with ICL who present with acute neurological signs and symptoms.

Keywords

Cryptococcal meningoencephalitis, idiopathic CD4 T cell lymphocytopenia, stroke mimic.

Key message

In an immunocompromised patient with acute neurological signs and symptoms a high index of suspicion for Cryptococcal meningoencephalitis must be kept and appropriate workup should be done.

Introduction

Cryptococcus neoformans is a fungal pathogen that causes a spectrum of disorders, including asymptomatic colonization of the lungs to severe meningitis and generalized infection in humans. The infection predominantly occurs in immunocompromised patients who are either HIV-positive or organ transplant recipients. However, severe Cryptococcal infections are also seen in apparently

immunocompetent hosts, including patients with idiopathic CD4 T cell lymphocytopenia (ICL). Atypical clinical presentation as stroke mimic is occasionally encountered in patients with Cryptococcal meningoencephalitis.

Case report

We are presenting a case of 80-year-old gentleman who presented to the Neurology department with acute onset right upper limb weakness, right upper limb ataxia, and loss of contact with surroundings. He had no history of fever, headache, vomiting, seizures, recent travel, or vaccination. He had a history of coronary artery disease, pulmonary embolism, and hypertension.

A clinical diagnosis of acute stroke was considered. CT brain showed left frontal lobar hypodensity. However, as the hypodensity did not correspond to any vascular territory, a CEMRI brain was done which showed focal left frontal leptomeningeal enhancement with focal cerebral edema (Figure 1). Blood workup including HIV 1/2 serology and western blot, HTLV 1/2 serology, VDRL, serum ACE, tumour markers, serum paraneoplastic encephalitis antibodies, serum autoimmune encephalitis antibodies, and anti-thyroid peroxidase antibody was unremarkable.

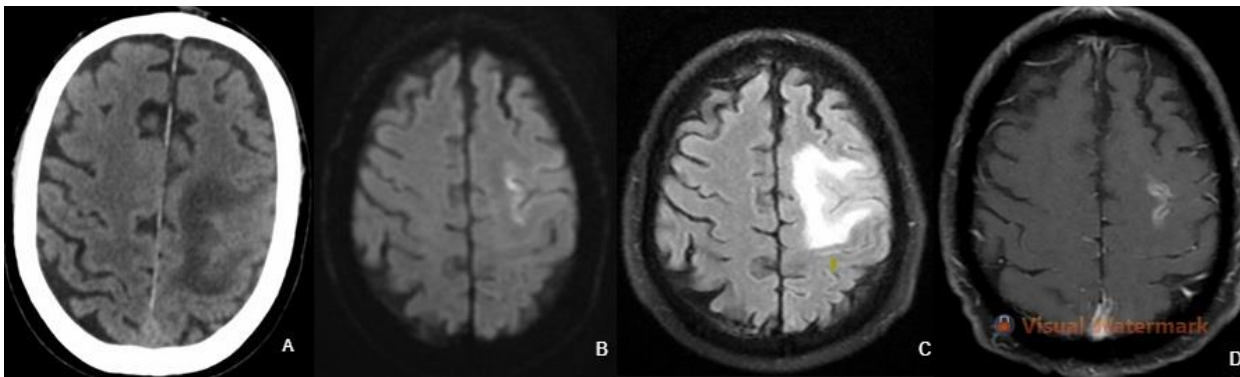


Figure-1.

- A. CT brain showing hypodensity in left frontal lobe with effacement of adjacent sulci.
- B. Left superior and inferior frontal sulcal based MRI diffusion restriction.
- C. MRI T2 FLAIR hyperintensity along left superior and inferior frontal sulci and gyri.
- D. Post Gd MRI T1 sequence showing left superior and inferior frontal sulcal based leptomeningeal enhancement.

CSF examination showed lymphocytic pleocytosis with raised protein and moderately low glucose. CSF for AFB stain, ADA, TB PCR, and KOH preparation were all negative. He was started on antitubercular treatment with steroids. He improved clinically over the next few days and was discharged with minimal weakness in right upper limb.

He was readmitted after two days with altered sensorium and fever. A repeat CEMRI brain showed mild improvement in the left frontal focal leptomeningeal enhancement and cerebral edema. However, a new diffuse leptomeningeal enhancement was noted (Figure 2). Blood workup showed hyponatremia. A repeat CSF examination showed raised cell count with polymorphic predominance with high protein and very low glucose concentrations. CSF India ink preparation showed budding yeast cells with pseudocapsule and CSF Cryptococcal antigen test was positive. CSF for malignant cell and autoimmune encephalitis antibody panel were negative. CD4 T lymphocyte count was low on two different occasions six weeks apart (106 and 275 cells/mm³), and he was diagnosed as ICL (Table 1).

Table-1. Laboratory investigations (First admission)

This publication is licensed under Creative Commons Attribution CC BY.

<https://dx.doi.org/10.29322/IJSRP.13.11.2023.p14330>

www.ijsrp.org

Haemoglobin - 10.9 g/dl	Blood urea - 45 mg/dl	Tumour markers - Negative	CSF cell count - 120 cells/ mm ³
Leucocyte Count - 7370 cells/ mm ³	Serum creatinine - 1.5 mg/dl	Serum PSA- 1.59 ng/ml	CSF glucose - 91 mg/dl
Platelet count - 290000 cells/ mm ³	Serum sodium - 138 mmol/L	Serum ACE - 35 U/L	CSF protein- 130 mg/dl
Autoimmune encephalitis panel - Negative	Serum potassium - 3.8 mmol/L	VDRL - Negative	CSF malignant cytology - Negative
Paraneoplastic antibody panel - Negative	Serum Albumin - 4.2 g/dl	HIV 1 & 2 - Negative	CSF KOH mount- Negative

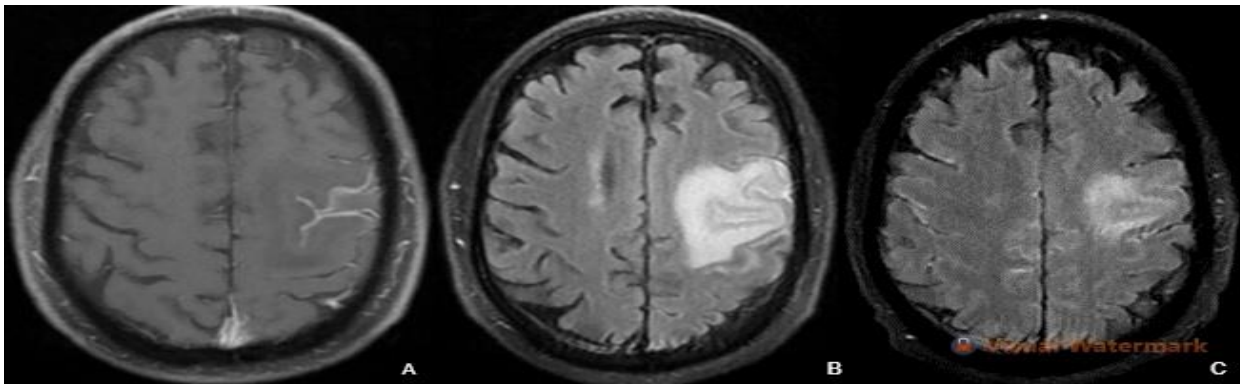


Figure-2.

- A. Post Gd MRI T1 sequence showing decreased leptomeningeal enhancement.
- B. MRI T2 FLAIR sequence showing hyperintensity along left frontal sulci with edema.
- C. Post Gd MRI T2 FLAIR sequence showing diffuse hyperintensity along sulci of both cerebral hemispheres.

He was started on liposomal amphotericin B and flucytosine, following which he had clinical improvement. His intensive phase of the treatment was punctuated by febrile neutropenia (absolute neutrophil count of 640 cells/mm³), for which G- CSF (filgrastim) was initiated. Flucytosine was stopped in view of imminent bone marrow suppression, and fluconazole was initiated. CSF examination was repeated two weeks after initiation of therapy, which showed moderately raised cell counts with mildly raised protein and low glucose. However, CSF KOH preparation showed clearance of fungal elements. CT brain revealed hydrocephalus (Figure 3). Ventriculoperitoneal shunting was done, following which he gradually improved and was discharged to his home.

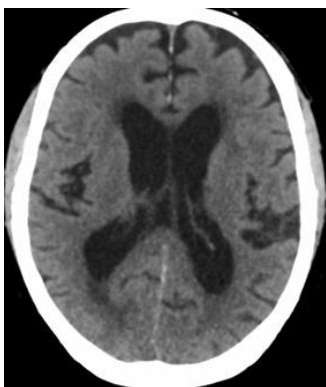


Figure-3.

CT Brain showing subtle hypodensity in left frontal lobe with early hydrocephalus.

Discussion

ICL is an immune deficiency first described and characterized by the US Centers for Disease Control in 1992 as an absolute CD4+ T lymphocyte count < 300 cells/mm³ or $< 20\%$ of total T cells on more than one occasion; no evidence of infection with HIV-1/2 or human T-cell lymphotropic virus 1/2 (HTLV-1/2); and lack of a defined immune-deficiency disease or therapy for lymphocytopenia.

ICL is a very rare disease and only a few hundred cases have been reported from all over the world so far. There is no apparent predilection to one geographical area. Patients are usually diagnosed in the middle of their age. No evidence of any transmissible agent has been described.¹ Several hypotheses have been proposed to explain the selective depletion of CD4 cells in ICL, which include increased apoptosis,² genetic defects,³ cytokine dysregulation,⁴ sequestration of CD4 cells⁵ and immune senescence.⁶

Patients with ICL typically present with opportunistic infections, malignancies, or autoimmune disorders. Ahmed et al had reviewed 259 cases of ICL patients and found Cryptococcal infections constituted more than one fourth of the cases. Cryptococcal meningitis was the most common infection, followed by pneumonia and osteomyelitis.⁷ In another study of 39 patients with ICL most common infections were due to Cryptococcus, HPV, and non-tuberculous mycobacteria.⁸ Zonios et al studied the symptomatology in 53 patients with ICL and Cryptococcosis. Among them headache and fever were the most common presenting symptoms, however, diplopia, confusion, imbalance, dizziness, photophobia, limb weakness, seizures, and slurred speech were also present in few patients.⁹ Several case reports have been documented where Cryptococcal meningoencephalitis presented atypically as a stroke mimic. Tahhan et al reported a HIV-positive patient with Cryptococcal meningoencephalitis who had signs and symptoms of a large right middle cerebral artery territory stroke but had only a subtle MRI diffusion restriction in the right frontal subcortical area.¹⁰ This patient was later diagnosed as Cryptococcal cerebritis. To our knowledge there are only few cases described where Cryptococcal meningoencephalitis has presented as stroke mimic.

Conclusion

Cryptococcal meningoencephalitis typically present in an immunocompromised patient with fever, headache, and altered sensorium. However, it may present atypically in some patients as a stroke mimic without any preceding fever or headache. Also, it may initially present as a focal leptomeningeal enhancement on neuroimaging prior to its more common manifestation of diffuse leptomeningeal enhancement. It is imperative to keep a high index of suspicion of Cryptococcal meningoencephalitis in immunocompromised patients with neurological manifestations.

References

1. Smith DK, Neal JJ, Holmberg SD. Unexplained opportunistic infections and CD4+T-lymphocytopenia without HIV infection. An investigation of cases in the United States. The centers for disease control idiopathic CD4+T-lymphocytopenia task force. *N Engl J Med* 1993;328:373-9
2. Laurence J, Mitra D, Steiner M, Lynch DH, Siegal FP, Staiano-Coico L, et al. Apoptotic depletion of CD4+ T cells in idiopathic CD4+ T lymphocytopenia. *The Journal of Clinical Investigation*. 1996 Feb 1;97(3):672-80.
3. Serwas NK, Cagdas D, Ban SA, Bienemann K, Salzer E, Tezcan İ, et al. Identification of ITK deficiency as a novel genetic cause of idiopathic CD4+ T-cell lymphopenia. *Blood, The Journal of the American Society of Hematology*. 2014 Jul 24;124(4):655-7.

4. Puronen CE, Thompson WL, Imamichi H, Beq S, Hodge JN, Rehm C, et al. Decreased interleukin 7 responsiveness of T lymphocytes in patients with idiopathic CD4 lymphopenia. *Journal of Infectious Diseases*. 2012 May 1;205(9):1382-90.
5. Kovacs SB, Sheikh V, Thompson WL, Morcock DR, Perez-Diez A, Yao MD, et al. T-cell depletion in the colonic mucosa of patients with idiopathic CD4+ lymphopenia. *The Journal of Infectious Diseases*. 2015 Nov 15;212(10):1579-87.
6. Bignon A, Régent A, Klipfel L, Desnoyer A, de la Grange P, Martinez V, et al. DUSP4-mediated accelerated T-cell senescence in idiopathic CD4 lymphopenia. *Blood, The Journal of the American Society of Hematology*. 2015 Apr 16;125(16):2507-18.
7. Ahmad DS, Esmadi M, Steinmann WC. Idiopathic CD4 lymphocytopenia: spectrum of opportunistic infections, malignancies, and autoimmune diseases. *Avicenna Journal of Medicine*. 2013 Apr;3(2):37-47.
8. Zonios DI, Falloon J, Bennett JE, Shaw PA, Chaitt D, Baseler MW, et al. Idiopathic CD4+ lymphocytopenia: natural history and prognostic factors. *Blood, The Journal of the American Society of Hematology*. 2008 Jul 15;112(2):287-94.
9. Zonios DI, Falloon J, Huang CY, Chaitt D, Bennett JE. Cryptococcosis and idiopathic CD4 lymphocytopenia. *Medicine (Baltimore)*. 2007; 86:78-92.
10. Tahhan F, Haritounian A, Duong L, Haugen J, Liu AK. Cryptococcus meningoencephalitis with severe localizing neurological deficits mimicking a large right middle cerebral artery infarct in a HIV patient. *Cureus*. 2021 Apr 30;13(4).

First Author – Dr. Sandeep Ghosh, DM, MD, MBBS, ECFMG, Accord Superspeciality Hospital

Second Author - Dr. Rohit Gupta, M.B.B.S, M.D, D.M, D.N.B, Accord Superspeciality Hospital

Third Author – Dr. Megha Sharda, M.B.B.S, M.D, D.N.B, Accord Superspeciality Hospital

Fourth Author - Dr. Sandip Bhattacharya, M.B.B.S, M.D (Internal Medicine), Accord Superspeciality Hospital

Fifth Author - Dr. Ashok Kumar Sharma, MBBS, DNB, IDCCM, IFCCM, FNB, Accord Superspeciality Hospital