

# Spiked Helmet Sign in Electrocardiogram, Sign of Hypomagnesaemia: A Case Study

Rameez Raja Najar \*

\* Department of Medicine, GMC Srinagar-190010, J&K India

DOI: 10.29322/IJSRP.10.11.2020.p10794

<http://dx.doi.org/10.29322/IJSRP.10.11.2020.p10794>

**Abstract:** Magnesium is the second most common intracellular cation and serves as an important metabolic cofactor to over 300 enzymatic reactions throughout the human body. Among its various roles, magnesium modulates calcium entry and release from sarcoplasmic reticulum and regulates ATP pumps in myocytes and neurons, thereby regulating cardiac and neuronal excitability. This paper reports a patient suffering from severe hypomagnesaemia. In whose electrocardiogram, a transient ST elevation, deep T wave inversions in inferior leads (II, III, AVF) and QT prolongation has been observed. The pattern in the electrocardiogram of that patient represents the sign of a Spiked helmet. This sign in electrocardiogram, thus, can be correlated with patients having severe deficiency of Mg and form a first-hand tool for investigating such patients.

## 1.1. Introduction

Magnesium has attracted attention as an essential element with diverse roles in the regulation of cardiac contraction. Chronic suboptimal intake of the element results in hypomagnesaemia. Reduction in extracellular magnesium affects myocardial excitability and contractility predominantly, by modulation of the levels of other ions that have an influence on cardiac mechanics. Electrical excitability is enhanced in magnesium deficiency, and arrhythmic changes are presumed to be mediated by disturbance in K<sup>+</sup> homeostasis [1]. Thiazide diuretics have frequently been recommended as initial therapy in patients with mild to moderate hypertension. However, their undesirable metabolic consequences have been suspected of contributing to increases in cardiovascular morbidity and mortality. Even at low doses, there is a definite decrease in both potassium and magnesium levels.[2].In a study, it has been seen that, electric stimulation (indirect via the nerve or direct) produced tetanic contractions and increased force at increasing stimulation frequencies. Significantly lower frequencies were needed to elicit these effects when intra- and extracellular Mg levels were low, in comparison to plentiful Mg supply. Comparing unstimulated and stimulated diaphragmatic tissue electrolyte concentrations revealed tissue losses of Mg, K Ca from stimulated tissues which were less pronounced when Mg supply was optimal.

The exact mechanism of the spiked helmet ECG pattern and its association with critical illness is uncertain, but several observations point to the possible role of the diaphragm. Certain pathological conditions can rarely result in repetitive contraction of the diaphragm that is in concert with the cardiac cycle [3, 4] Postulated mechanisms of this pulsatile diaphragmatic motion include direct stimulation of the diaphragm by the inferior wall of the left ventricle or triggering of the left leaf of the diaphragm by the left phrenic nerve Such diaphragmatic contractions may result in alteration of the ST segment, which is best seen in the inferior leads [5, 6, 7]. Hypomagnesaemia is common, occurring in about 20% of hospitalized patients and up to 65% of critically ill patients [8, 9]. Hypomagnesaemia is generally asymptomatic. Symptoms commonly occur once the serum magnesium concentration falls below 1.2 mg/dl [10].

## 1.2. Case History and Discussion

A 57 year old female known hypertensive, type-II diabetes and DCM (EF 28%) on diuretics presented with dizziness in the department of cardiology SMHS Hospital Srinagar Kashmir. She gave history of palpitations also prior to dizziness. However, the clinical examination of the patient was normal. Then, the patient was subjected to Electrocardiography, the details of which are shown in Fig. 1.1.

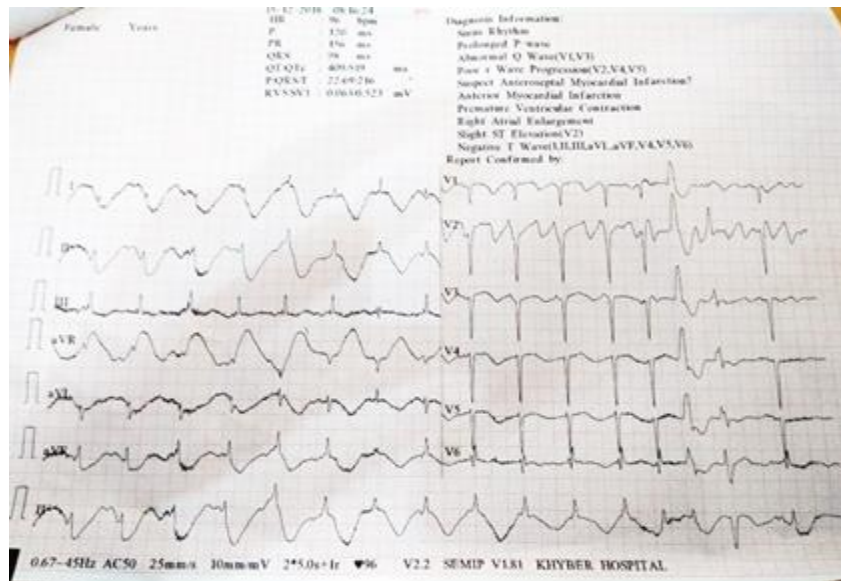


Fig 1.1: Electrocardiogram before treatment

Electrocardiography revealing poor R wave progression, T wave inversions in I, II, III, AVF leads, QT Prolongation with apparent ST-segment elevation and the upward shift starting before the onset of the QRS complex (Fig. 1.1). The ECG report obtained for the present case looks similar to what has already been reported [11]. That showed a dome-and-spike pattern, giving the appearance of Pickelhaube, the German military spiked helmet introduced in 1842 by Friedrich Wilhelm IV, King of Prussia<sup>1</sup> as shown in Fig.1.2.

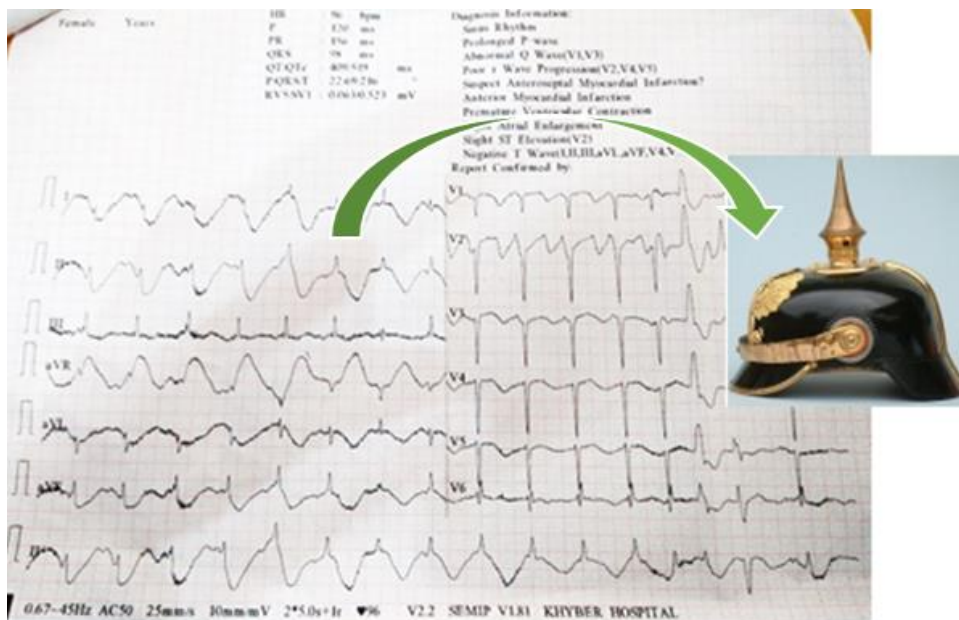


Fig.1.2: Electrocardiogram resembling to Spiked Helmet

Table 1.1 shows the hematological and other laboratory parameters of the patient.

**Hematological and other Laboratory parameters**

VARIABLES	RESULTS
Hemogram (g/dl)	11.4
White cell count (per mm <sup>3</sup> )	7800

<b>Platelet count(per mm<sup>3</sup>)</b>	1.64 lac
<b>Urea (mg/dl)</b>	54
<b>Creatinine (mg/dl)</b>	1.3
<b>Bilirubin (mg/dl)</b>	1.1
<b>Aspartate transaminase (U/L)</b>	34
<b>Alanine transaminase (U/L)</b>	31
<b>Glucose (mg/dl)</b>	102
<b>Calcium( mg/dl)</b>	8.2
<b>Magnesium (mg/dl)</b>	<b>1.18* (0.06mmol/L)</b>
<b>Potassium (mg /dl)</b>	2.78

Table1.1

Clearly, the patient is having anemia with mild renal involvement (eGFR =42 ml/min/1.73m<sup>2</sup>). However ultrasonography abdomen showed normal sized kidneys, and echo texture and CMD maintained. Her liver functions were normal. We found severe hypomagnesaemia\* and mild hypokalemia. However serum calcium was lower normal. Echocardiography of this patient revealed DCM, severe LV dysfunction [EF 28%], RWMA. Her cardiac markers were negative (Troponins).

After treatment with intravenous magnesium of 2 gm stat given over 5 minutes. The patient was then followed by 4 gm intravenous infusion over 24 hrs and the dose was repeated as necessary to main the plasma concentration above 1 mg/dl. Patient’s reduced renal functions were taken into consideration while treating the patient. The patient seems recovering within minutes and the Spiked Helmet pattern in the patient’s electrocardiogram disappears as is clearly visible in Fig. 1.3.

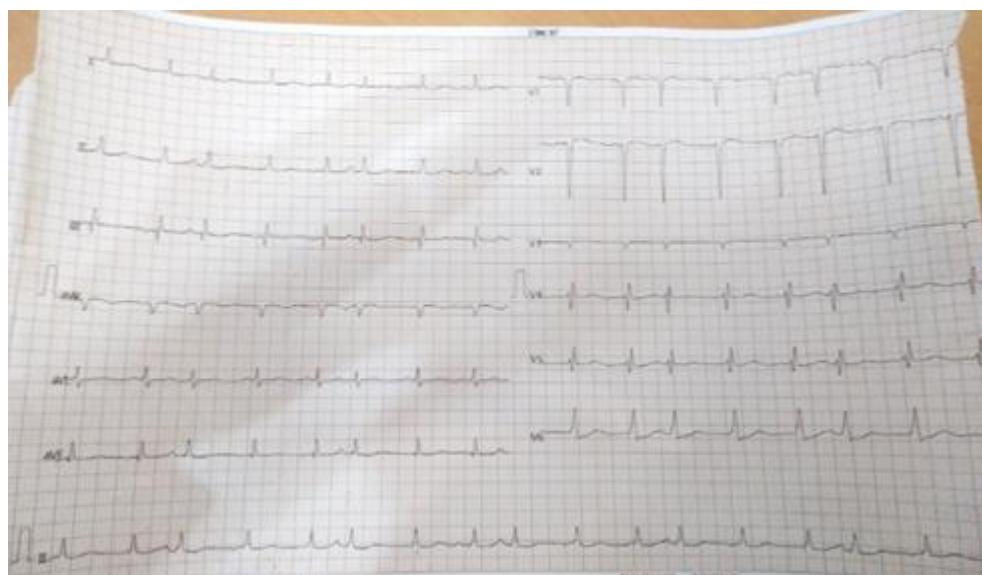

Fig. 1.3: Electrocardiogram after treatment

What we infer from the case is that since the postulated mechanism for Spiked Helmet sign in electrocardiogram is the result in repetitive contraction of the diaphragm that is in concert with the cardiac cycle. We know hypomagnesaemia increases the excitability of muscle cells, thus increases the contractions of cardiac muscle. The patient had severe hypomagnesaemia and that could be the reason for Spiked Helmet sign in electrocardiogram which is a rare presentation. Cardiac and neuronal dysregulation (palpitation and dizziness) secondary to severe hypomagnesemia subsided with normalization of magnesium. We have seen normalization of

electrocardiogram with normal magnesium levels. Moreover this sign is a marker of high mortality. Spiked helmet sign which is known to occur in critically ill patients, the only reason could be hypomagnesaemia in them.

### 3.3. Conclusion

Electrocardiography is a cheapest and highly informative investigation available to us and will predict the mortality associated with the level of hypomagnesaemia. The Spiked helmet sign, as seen in non-cardiac illnesses like hypomagnesaemia, in electrocardiogram provides a first-hand tool to analyze the severity of the deficiency of Mg.

**Conflict of Interest:** There is no conflict of interest with the Institute from where the work has been carried out.

### References

- [1] Nair RR1, Nair P. Alteration of myocardial mechanics in marginal magnesium deficiency *Magnes Res.* 2002 Dec; 15 (3-4):287-306.
- [2] Hollifield J. Electrolyte disarray and cardiovascular disease. *Am J Cardiol.* 1989; 63:21–26.
- [3] Schindler R1, Thöni H, Classen HG. The role of magnesium in the generation and therapy of benign muscle cramps. Combined in-vivo/in-vitro studies on rat phrenic nerve-diaphragm preparations. *Arzneimittelforschung.* 1998 Feb; 48(2):161-6. 2.
- [4] Sjoerdsma A, Gaynor WB. Contraction of left leaf of diaphragm coincident with cardiac systole. *J Am Med Assoc.* 1954; 154(12):987–989.
- [5] Frye RL, Braunwald E. Bilateral diaphragmatic contraction synchronous with cardiac systole. *N Engl J Med.* 1960; 263(16):775–778.
- [6] Aslanger E, Yalin K. Electromechanical association: a subtle electrocardiogram artifact *J Electrocardiol.* 10.1016/j.jelectrocard.2010.12.162.
- [7] Brearley WD, Jr, Taylor L, III, Haley MW, Littmann L. Pneumomediastinum mimicking ST-segment elevation myocardial infarction. *Int J Cardiol.* 2007;117(2):e73–e75
- [8] G. M. Tong and R. K. Rude, “Magnesium deficiency in critical illness,” *Journal of Intensive Care Medicine*, vol. 20, no. 1, pp. 3–17, 2005.
- [9] E. Ryzen, “Magnesium homeostasis in critically ill patients,” *Magnesium*, vol. 8, no. 3-4, pp. 201–212, 1989.
- [10] Z. Angus, “Hypomagnesemia,” *Journal of the American Society of Nephrology*, vol. 10, pp. 1616–1622, 1999.
- [11] Laszlo Littmann, Michael H. Monroe. The “Spiked Helmet” Sign: A New Electrocardiographic Marker of Critical Illness and High Risk of Death. *Mayo Clin Proc.* 2011 Dec; 86(12): 1245–1246.10.4065/mcp.2011.0647