

The Relationship Between Immunohistochemical Expression Of Vitamin D Receptor (VDR) With Tumor-Associated Stromal Cells (TASCs) And Histopathological Grading In Prostate Adenocarcinoma

Zuhri Madriah*, T. Ibnu Alferally*, Jessy Chrestella*

Department of Anatomical Pathology, Faculty of Medicine, Universitas Sumatera Utara, Medan, Indonesia.

*Corresponding Author

DOI: 10.29322/IJSRP.12.09.2022.p12925
<http://dx.doi.org/10.29322/IJSRP.12.09.2022.p12925>

Paper Received Date: 5th August 2022
Paper Acceptance Date: 6th September 2022
Paper Publication Date: 15th September 2022

Abstract: In few studies, the exposure of ultraviolet and vitamin D serum levels has been linked to prostate cancer. To date, there are controversy about research results and still no studies linking VDR directly with TASCs in prostate cancer.

Objective: To assess the relationship between immunohistochemical expression of VDR with TASCs and histopathological grading in prostate adenocarcinoma.

Materials and Methods: This analytic study with cross sectional approach used 35 samples from paraffin blocks from patients histopathologically diagnosed as prostate adenocarcinoma. Grading of these samples were assessed and Masson's trichrome histochemistry (for TASCs) and VDR immunohistochemical staining were performed. All results were analyzed using Chi Square or Pearson chi square.

Results and Discussion: There was statistically significant relationship between immunohistochemical expression of VDR with histopathological grading and grade group, with moderate strength value ($r=0.381$) and p value <0.05 . But, no statistically significant relationship between immunohistochemical expression of VDR and TASCs in prostate adenocarcinoma.

Conclusion: Further studies are needed to compare vitamin D blood levels with immunohistochemical expression of VDR in prostate tissue. Also, further researchers are needed to relate TGF β with TASCs and immunohistochemical expression of VDR in prostate adenocarcinoma. In these samples, it is also necessary to further investigate the VDR SNP gene.

Keywords: vitamin D, VDR, prostate adenocarcinoma, TASCs

I. INTRODUCTION

Prostate adenocarcinoma is an invasive carcinoma consisting of neoplastic prostate epithelial cells with differentiation and secretion arranged in various histomorphological patterns. In this carcinoma, basal cells are generally not found.¹ Prostate

adenocarcinoma is one of leading causes of death in men. Each year 1.6 million men are diagnosed as prostate adenocarcinoma and 366,000 men die because of this tumor around the world.² In North Sumatra in 2016, prostate cancer ranked in 4th after lung, cervical, and breast cancer with 42 cases.³ In Medan in 2014 based on health center recapitulation, there were 99 prostate cancer patients ranking in 2nd after breast cancer (499 cases).⁴

Prostate gland consists of epithelial and stroma compartment separated by basal membrane^{5,6}. Cells in these two compartments maintain an active two-way communication through paracrine mechanism whereby ligands and receptors are shared between these two compartments. This mutual communication is balanced and important for maintaining tissue homeostatis.⁵ Stroma of prostate gland is composed of fibroblasts, smooth muscle cells, and extracellular matrix (ECM) rich in collagen fibers lying between the glands. The existence of repeated and continuous epithelial injuries throughout the aging process and at the same time androgen hormone also needed to regulate the prostate gland, cause biological change of the prostate which is from reproductive function to chronic wound repair function. The biologic condition of this wound repair is the key in driving the development of different prostate diseases, all of which are found in both TASC and inflammation.⁶

TASCs are referred as new stromal environment that occur as a result of the response to carcinoma.⁷ These TASCs are described as microenvironment located adjacent to the epithelium that are able to coordinate several activities (wound repair, changes in homeostasis and interactions with neoplastic complexes).^{5,7} Tumor microenvironment include mesenchymal/stromal stem cells, endothelial cells, fibroblasts, myofibroblasts, immune cells, and neural crest cells, all of which secrete factors such as chemokines, cytokines, ECM, and matrix-degrading enzymes.^{5,8-10} Prostatic TASCs promote prostate cancer progression by supporting tumor cell proliferation, inducing fibroblastic phenotype, changing the shape of ECM, and increasing the likelihood of metastasis.⁵

Because prostate cancer-associated TASCs consist of cancer-associated fibroblasts cells (CAF) that occur concomitantly with reduced or complete loss of smooth muscle cells, these changes can be easily seen using simple histochemical methods such as Mallory or Masson's trichrome staining.^{11,12} These CAFs are most often regulated through transforming growth factor (TGF β) signaling pathway.¹³ The presence of TGF β upregulation supports the formation of TASCs, induces epithelial-to-mesenchymal transition (EMT), and induces VDR expression in WPMY-1 human prostate stromal cell line.^{13,14} This VDR mediates the action of vitamin D hormone and can affect prostate tissue.¹⁵ Vitamin D has been known as a hormone to have a lower risk of several types of cancer, including prostate cancer.¹⁶

On the other hand, this TGF- β can increase the upregulation of CYP24A1 (functions to metabolize 1,25D3 into an inactive form which will then be excreted in the urine) induced by 1,25D3. The increased expression of CYP24A1 in the tumor microenvironment can increase the metabolism of 1,25D3 thereby reducing its availability. Therefore, the high expression of TGF β in tumors and stroma may have negative impact on 1,25 D3 therapy.¹⁴ This is also confirmed by the study of Ding et al, who found that the anti-tumor effect of 1,25D3 was due to TGF- β inhibition mediated by the interaction between ligand-bound VDR and the transcription factor Smad3 which was activated by TGF- β .¹⁵ The differences in these study results coupled with the absence of studies linking VDR directly with TASCs in prostate cancer cause researchers to be interested in looking at the relationship of VDR immunohistochemical expression with TASCs and histopathological grading of prostate adenocarcinoma.

II. MATERIAL AND METHODS

Sample selection

This analytic research with cross sectional approach was done in General Hospital H. Adam Malik Medan/ Department of Anatomical Pathology, Medical Faculty USU. This study was conducted from December 2021 until March 2022, after receiving approval from Health Research Ethics Committee, Medical Faculty Universitas Sumatera Utara Medan.

Study samples were gathered from paraffin blocks from patients diagnosed as prostate adenocarcinoma cases in General Hospital H. Adam Malik Medan/ Department of Anatomical Pathology, Medical Faculty USU fulfilling inclusion and exclusion criteria. Samples were gathered by using consecutive sampling. Inclusion criteria in this study were paraffin blocks from TURP, prostatectomy and core biopsy specimens that has been histopathologically diagnosed as prostate adenocarcinoma, are adequate after stained with hematoxylin-eosin. Meanwhile, exclusion criteria were paraffin blocks with core biopsy specimens <10, and paraffin blocks/ slides that are not fulfilling standard (damaged, etc.). VDR expression was determined as dependent variable and histopathological grading and TASCs

were determined as independent variables. Each sample was stained with HE, Masson's trichrome histochemistry and VDR polyclonal antibody immunohistochemistry (Bioassay technology laboratory, dilution 1:100-1:300).

To evaluate histopathological grading in this study, the researchers use two versions, which are based on Gleason score and grade group. According to Gleason score, histopathological grading are categorized into well differentiated (Gleason score ≤ 6), moderately differentiated (Gleason score 7), and poorly differentiated (Gleason score 8 – 10).¹⁴ On the other hand, based on grade group, histopathological grading are categorized into: Grade group 1 (Gleason score ≤ 6), Grade group 2 (Gleason score 3+4), Grade group 3 (Gleason score 4+3), Grade group 4 (Gleason score 4+4=8, 3+5=8, 5+3=8), and Grade group 5 (Gleason score 9–10).¹⁶

TASCs assessed using Masson's trichrome staining were categorized into 4 groups. If no blue color was found in the stroma around malignant prostate gland, it was determined as (-). If found 1-15% blue color in the stroma around malignant prostate gland, it was assessed as (+). If there was 15-50% blue color in the stroma around malignant prostate gland, it was assessed as (++) . When found >50% blue color in the stroma around the prostate gland, it was assessed as (+++).¹⁷ Then, VDR expression was interpreted by adding the area scores with the intensity scores. Total area was done as follows: score 0 (if no positive stained nuclei and cytoplasm), score 1 (<10% of positive stained nuclei and cytoplasm), score 2 (10-50% of positive stained cells), and score 3 (>50% of positive stained cells. Meanwhile, intensity was scored as follows: 0 (none), 1 (weak, light brown), 2 (moderate), and 3 (strong, dark brown). After that, the total score of VDR expression was categorized as weak (if total score ≤ 2), moderate (if total score 3-4), and strong (total score 5-6).¹⁸

Data analysis

Data collected in this research were processed by using statistical software and analyzed using Chi Square Test or Pearson Chi Square Test.

III. RESULTS

In this study, 35 samples with prostate adenocarcinoma diagnosis in Department of Anatomic Pathology, Faculty of Medicine, Universitas Sumatera Utara and Anatomic Pathology Unit, General Hospital Haji Adam Malik Medan were obtained. In this study, analysis about relationship about VDR immunohistochemical expression with TASCs and grading histopathology was done. Pearson chi square test analysis found statistically significant relationship between VDR immunohistochemical expression with grading histopathology and grade group, with moderate strength value ($r=0.381$) and p value <0.05. But, no statistically significant relationship between immunohistochemical expression of VDR and TASCs in prostate adenocarcinoma ($p>0.05$) (Table 1).

Table 1. Relationship between VDR immunohistochemical expression with TASCs and grading histopathology in prostate adenocarcinoma.

Variables	weak		VDR expression moderate		strong		p value
	count	%	count	%	count	%	
TASCs							
(-)	0	0	0	0	0	0	0,376*
(+)	2	22,2	6	24,0	0	0	
(++)	1	11,1	6	24,0	1	100	
(+++)	6	66,7	13	52,0	0	0	
Grading							
Well differentiated	0	0	4	16	0	0	0,038*
Moderately differentiated	5	55,6	3	12	1	100	
Poorly differentiated	4	44,4	18	72	0	0	
Grade group							
1	0	0	4	16,0	0	0	0,009*
2	3	33,3	3	12,0	1	100	
3	2	22,2	0	0	0	0	
4	4	44,4	4	16,0	0	0	
5	0	0	14	56,0	0	0	
Total	9	100	25	100	1	100	

NB: * Pearson chi square test

Figure 1. Interpretation of VDR immunohistochemical staining.

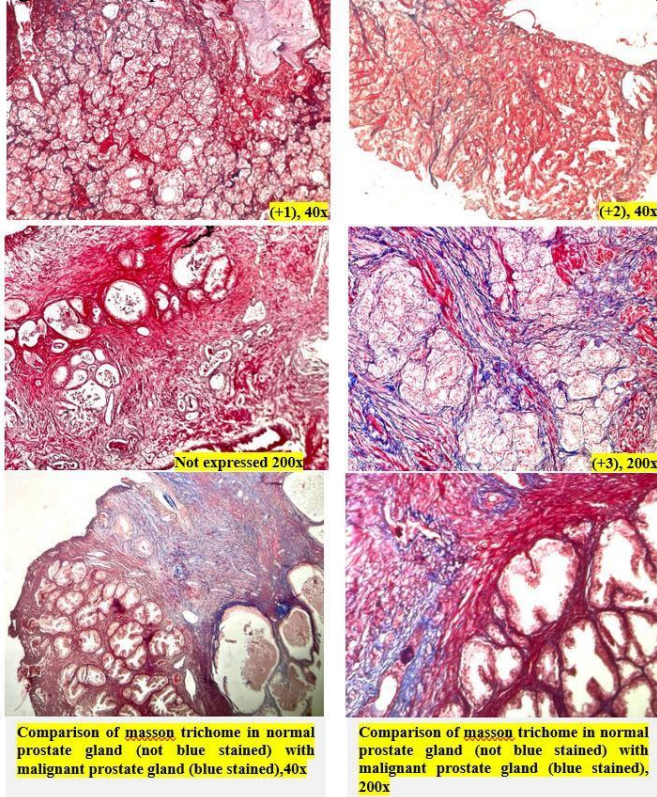
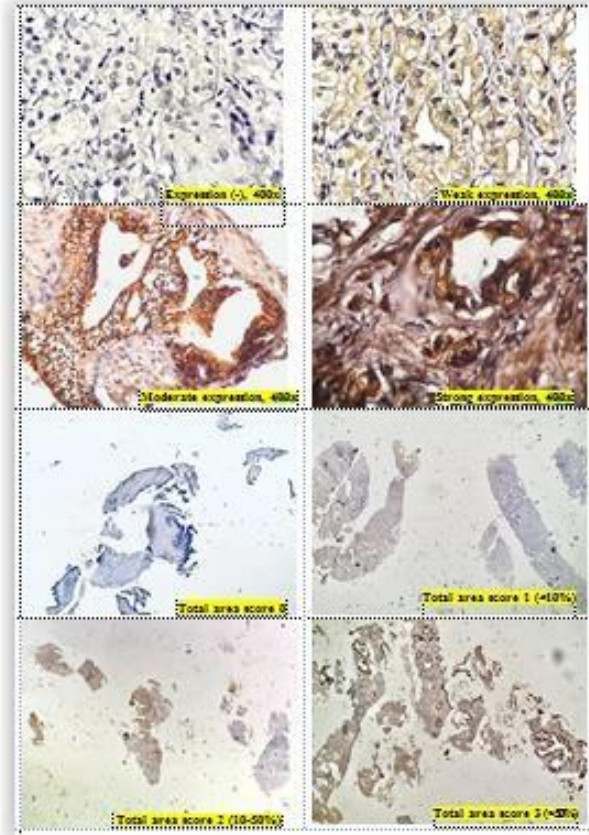


Figure 2. Interpretation of Masson's trichrome histochemical staining.

IV. DISCUSSION

The role of vitamin D has been widely studied in various diseases and type of cancer.¹⁹ Vitamin D has been proposed to have anti-cancer abilities, especially through its nuclear receptor activity or VDR.^{18,20} This VDR expression can be overexpressed or underexpressed in various cancer.^{21,23} As previously mentioned, TASCs are determined as microenvironment located adjacent to the epithelium that is able to coordinate several activities such as wound repair, homeostatic changes and interactions with neoplastic complexes.^{5,7} These TASCs promote prostate cancer progression by supporting tumor cell proliferation, inducing a fibroblastic phenotype, changing the shape of the ECM, and increasing the likelihood of metastasis.⁵ In cancer, it is known that carcinoma cells have the cap



acuity to induce normal fibroblasts into a reactive myofibroblast phenotype.^{12,16} To examine these cells in TASCs associated with prostate cancer, this study used Masson's trichrome staining.^{11,12} In this study, it was found that from 35 samples, there were about 54.3% samples had >50% of the stroma around the prostate gland stained blue (group +++), 22.9% samples had ≤15% stroma stained blue (group +), and 22.9% samples had ?15-<50% stroma stained blue (group ++). The results of this study was in line with Hilbertina and Mulyani who found that all carcinoma specimens had TASCs > 15%. The higher the degree of histopathology, the higher the percentage of TASCs and this relationship is strong and statistically significant.¹⁶

Then, in this study, the relationship between VDR immunohistochemical expression and TASCs in prostate

adenocarcinoma was determined. By using Pearson chi square, no statistically significant relationship between VDR immunohistochemical expression and TASCs in prostate adenocarcinoma was found ($p > 0.05$). So far, there are still no published studies examining the relationship between VDR expression and TASCs in prostate adenocarcinoma. Therefore, it cannot be compared with other studies.

According to the literature, it is known that carcinoma cells have the capacity to induce normal fibroblasts into a reactive myofibroblast phenotype (CAF).^{12,16} These CAFs are most often regulated through TGF β signaling pathway.¹³ TGF β upregulation supports angiogenesis and the formation of TASCs through matrix production (fibronectin, elastin, type I collagen) and release of factors responsible for extracellular remodelling (metalloproteinases and their inhibitors). Moreover, TGF β activation induces EMT and VDR expression in the human WPMY-1 prostate stromal cell line.^{13,14} Increased levels of IL-6 secretion from CAFs are thought to be a mechanism for the development of prostate cancer that is not dependent on androgen hormones through the PI3K-AKT, STAT3 and MAPK/ERK pathways. Activated stromal cells react with each other.¹³ Based on this study's results, it can be concluded that there appears to be no direct association between VDR and the onset of TASCs. Based on the theory, it seems that TGF β is the one that causes TASCs and induces VDR expression. Therefore, it is necessary to further investigate whether this TGF β is indeed directly and separately causes TASCs and induces VDR expression. So, it can be concluded that TGF β does not directly affect the occurrence of TASCs.

In addition, based on grading, this study found a statistically significant relationship between VDR immunohistochemical expression with both histopathological grading and group grade, with moderate strength value ($r = 0.381$; p value < 0.05). There is controversy from several previous studies' results.²⁴⁻²⁶ The results of this study was in line with Hendrickson et al. They found that men with high expression of VDR protein tumour had better clinical characteristics, including lower Gleason scores. They also found that VDR expression was highest in tumour with Gleason 3+3 and decreased with Gleason scores ($p < 0.001$).²⁵ Currently, molecular biology has developed very rapidly. The VDR gene is found on chromosome 12q13.11 and is polymorphic with at least 618 variants found. There have been several previous studies regarding single nucleotide polymorphisms (SNPs) in the VDR gene. As in the study of Jingwi et al, it was found that there was an association between SNP VDR and Gleason scores in prostate adenocarcinoma, which was the relationship between BsmI genotypes and rs2239185 with high Gleason scores.²⁷ Because in this study, there was VDR expression in all histopathological grading. This led researchers to think that there may be certain VDR SNPs that tend to have higher or lower levels. Therefore, it is necessary to conduct further research on VDR SNPs in this sample group. However, in contrast to Ginting et al, they found no difference between VDR expression and prostate adenocarcinoma grade groups. In addition, it was also found that in all groups, moderate VDR expression was higher than strong expression.²⁸

Increased expression of VDR in colorectal cancer is associated with better tumour differentiation, absence of lymph node involvement and better prognosis.²⁵ In the study of Erida et

al, it appeared that there is a strong correlation between VDR immunoeexpression and the degree of differentiation in colorectal adenocarcinoma. It was found that VDR correlated with the low grade group so that targeted therapy with vitamin D or its active form, calcitriol, could be given to the low grade group. An increased number of VDRs in tumour tissue responds to calcitriol therapy as the active form of the vitamin D metabolite.²⁹ Aminah et al and Kure et al also found that VDR expression was less common in high grade tumours than in low grade colorectal adenocarcinomas. They also found an association between VDR immunoeexpression and the degree of differentiation in colorectal adenocarcinoma.^{30,31} A recent study of VDR protein expression in 841 prostate cancer patients found that patients with high VDR expression had decreased Gleason score and stagnant tumour stages; it significantly reduces the risk of a lethal malignancy of prostate cancer.^{24,26}

The results of this study and several previous studies proved the same thing. VDR expression began to increase at the beginning of carcinogenesis or increase in the human colonic and prostate mucosa during early tumour development, but the level became low in poorly differentiated. This proved that VDR has the effect of restraining the growth of tumour cells. The results of this study have proven the role of VDR in the development of the pathogenesis of prostate adenocarcinoma so that vitamin D and its synthetic analogues can be used as adjuvant therapy in prostate cancer patients with positive VDR expression. If there is downregulation of the VDR, it will cause unresponsiveness and resistance not only to 1,25(OH)2D3 analog therapy but also the antitumoral effects of endogenous 1,25(OH)2D3. In this study, a polyclonal antibody VDR was used, where the VDR here specifically encoded the hormone receptor for vitamin D3. Therefore, the treatment given for this VDR is cholecalciferol-D3.

During this study, there was difficulty experienced by researchers. First of all, in determining the grading, some of the samples were from core biopsy, so it is difficult for the researchers to obtain good enough tumour specimens. It is feared that it does not represent the Gleason score and VDR expression. Second, in assessing VDR expression, the intensity of the brown color that appeared was not too different.

There were limitations encountered in this research. First, the researchers only evaluate the amount of VDR in tissues and not in blood samples. Therefore, it can't describe the actual vitamin D levels in the samples.

V. CONCLUSION

In this study, some conclusion could be emphasized. There was statistically significant relationship between immunohistochemical expression of VDR with histopathological grading and grade group, with moderate strength value ($r = 0.381$) and p value < 0.05 . But, no statistically significant relationship between immunohistochemical expression of VDR and TASCs in prostate adenocarcinoma.

VI. COMPETING INTERESTS

The author has no financial interests relevant to the product or company described in this article.

VI. ACKNOWLEDGMENT

We would like to thank all staff of the Department of Anatomical Pathology, University of North Sumatra, Private hospitals and private clinics in Medan, Indonesia for all their assistance and cooperation.

VII. ETHICAL APPROVAL

Health Research Ethical Committee, Universitas Sumatera Utara, Medan, Indonesia approved this study.

REFERENCES

- [1] Ulbright TM, Amin MB, Balzer B, Berney DM, Epstein JI, Guo C, Idrees MT, *et al.* Germ Cell Tumours: Seminoma. In: Moch H, Humphrey PA, Ulbright TM, Reuter VE (eds). World Health Organization Classification of Tumours of the Urinary System and Male Genital Organs, 4th ed. Lyon-France: IARC; 2016. p. 203–4.
- [2] Perner CH, Ebot EM, Wilson KM, Mucci LA. The Epidemiology of Prostate Cancer. *Cold Spring Harb Perspect Med.* 2018 Dec; 8(12):1–19. doi: 10.1101/cshperspect.a030361.
- [3] Irawan D. Penderita Kanker Banyak Terima Informasi Keliru [Internet]. 2017 [Cited on 1st October 2020]. Available from: http://koran-sindo.com/page/news/2017-05-21/4/23/Penderita_Kanker_Banyak_Terima_Informasi_Keliru.
- [4] Prawira, Munthe L. Kanker Payudara Masih Tinggi [Internet]. 2015 [Cited on 23rd September 2020]. Available from: <http://www.mdn.biz.id/n/145907/>.
- [5] Huang Y, Jin C, Hamana T, Liu J, Wang C, An L, McKeehan WL, *et al.* Overexpression of FGF9 in Prostate Epithelial Cells Augments Reactive Stroma Formation and Promotes Prostate Cancer Progression. *Int J Biol Sci.* 2015;11(8):948–60. doi:10.7150/ijbs.12468.
- [6] Barron DA and Rowley DR. The Reactive Stroma Microenvironment and Prostate Cancer Progression. *Endocr Relat Cancer.* 2012;19(6):187–204. doi:10.1530/ERC-12-0085.
- [7] Junior MMDS, Matheus WE, Garcia PV, Stopiglia RM, Billis A, Ferreira U, Favaro WJ. Characterization of Reactive Stroma in Prostate Cancer: Involvement of Growth Factors, Metalloproteinase Matrix, Sexual Hormones Receptors and Prostatic Stem Cells. *Int Braz J Urol.* 2015;41:849–58. doi: 10.1590/S1677-5538.IBJU.2014.0355.
- [8] Bahmad HF, Jalloul M, Azar J, Moubarak MM, Samad TA, Mukherji D, Al-Sayegh M, *et al.* Tumor Microenvironment in Prostate Cancer: Toward Identification of Novel Molecular Biomarkers for Diagnosis, Prognosis, and Therapy Development. *Front Genet.* 2021;12:652747. doi: 10.3389/fgene.2021.652747.
- [9] Cheng HS, Lee JXT, Wahli W, Tan NS. Exploiting Vulnerabilities of Cancer by Targeting Nuclear Receptors of Stromal Cells in Tumor Microenvironment. *Molecular Cancer.* 2019;18:51. doi: 10.1186/s12943-019-0971-9.
- [10] Bonollo F, Thalmann GN, de Julio MK, Karkampouna S. The Role of Cancer-Associated Fibroblasts in Prostate Cancer Tumorigenesis. *Cancers.* 2020;12:1887. doi: 10.3390/cancers12071887.
- [11] Stoll H and Robak HS. Metabolic Biomarkers and Reactive Stroma Grading in Human Prostate Cancer Tissue [Thesis]. Trondheim: Norwegian University of Science and Technology; 2015.
- [12] Kruslin B, Ulamec M, Tomas D. Prostate Cancer Stroma: An Important Factor in Cancer Growth and Progression. *BJBMS.* 2015. doi: 10.17305/bjbm.2015.449.
- [13] Sejda A, Sigorski D, Gulczynski J, Wesolowski W, Kitlinska J, Izycka-Swieszewska E. Complexity of Neural Component of Tumor Microenvironment in Prostate Cancer. *Pathobiology.* 2020;87:87–99. doi: 10.1159/000505437.
- [14] Solomon JD, Heitzer MD, Liu TT, Beumer JH, Parise RA, Normolle DP, Leach DA, *et al.* VDR Activity is Differentially Affected by Hic-5 in Prostate Cancer and Stromal Cells. *Mol Cancer Res.* 2014;12(8):1166–80. doi:10.1158/1541-7786.MCR-13-0395.
- [15] Ding N, Yu RT, Subramaniam N, Sherman MH, Wilson C, Rao R, Leblanc M, *et al.* A Vitamin D Receptor/ SMAD Genomic Circuit Gates Hepatic Fibrotic Response. *Cell.* 2013;153(3):601–13. doi: 10.1016/j.cell.2013.03.028.
- [16] Hendrickson WK, Flavin R, Kasperzyk JL, Fiorentino M, Fang F, Lis R, *et al.* Vitamin D Receptor Protein Expression in Tumor Tissue and Prostate Cancer Progression. *J Clin Oncol.* 2011 Jun; 29(17):2378–85. doi: 10.1200/JCO.2010.30.9880.
- [17] Hilbertina N and Mulyani H. Hubungan Persentase dan Pola Stroma Reaktif dengan Derajat Histopatologi Lesi Prostat. *Majalah Kedokteran Andalas.* 2011;2(35):106–16.
- [18] Pike JW, Meyer MB. The Vitamin D Receptor: New Paradigms for the Regulation of Gene Expression by 1,25-Dihydroxyvitamin D₃. *Rheum Dis Clin North Am.* 2012 Feb; 38(1):13–27.
- [19] Krill D, DeFlavia P, Dhir R, Luo J, Becich MJ, Lehman E, *et al.* Expression Patterns of Vitamin D Receptor in Human Prostate. *J Cell Biochem.* 2001 Sep; 82(4):566–72. doi:10.1002/jcb.1185.
- [20] Mizwicki MT, Norman AW. The Vitamin D Sterol-Vitamin D Receptor Ensemble Model Offers Unique Insights into Both Genomic and Rapid-Response Signaling. *Sci Signal.* 2009 Jun 16; 2(75):re4–re4. doi: 10.1126/scisignal.275re4.
- [21] Carlberg C and Munoz A. An Update on Vitamin D Signaling and Cancer. *Seminars in Cancer Biology.* 2020. doi: 10.1016/j.semcancer.2020.05.018.
- [22] Al-Azhri J, Zhang Y, Bshara W, Zirpoli G, McCann SE, Khoury T, Morrison CD, *et al.* Tumor Expression of Vitamin D Receptor and Breast Cancer Histopathological Characteristics and Prognosis. *Clin Cancer Res.* 2016;23(1):97–103.
- [23] Trivedi T, Zheng Y, Fournier PGJ, Murthy S, John S, Schillo S, Dunstan CR, *et al.* The Vitamin D Receptor is Involved in the Regulation of Human Breast Cancer Cell Growth Via A Ligand-Independent Function in Cytoplasm. *Oncotarget.* 2017;8(16):22687–701.
- [24] Hendrickson WK, Flavin R, Kasperzyk JL, Fiorentino M, Fang F, Lis R, *et al.* Vitamin D Receptor Protein Expression in Tumor Tissue and Prostate Cancer Progression. *J Clin Oncol.* 2011 Jun; 29(17):2378–85. doi: 10.1200/JCO.2010.30.9880.
- [25] Larriba MJ and Munoz A. Mechanisms of Resistance to Vitamin D Action in Human Cancer Cells. In: Holick M (ed). *Vitamin D Nutrition and Health.* USA: Humana Press; 2010. doi:10.1007/978-1-60327-303-9_15.
- [26] Swami S, Krishnan A V, Feldman D. Vitamin D Metabolism and Action in the Prostate: Implications for Health and Disease. *Mol Cell Endocrinol.* 2011 Dec; 347(1–2):61–9. doi:10.1016/j.mce.2011.05.010.
- [27] Jingwi EY, Abbas M, Ricks-Santi L, Winchester D, Beyene D, Day A, *et al.* Vitamin D Receptor Genetic Polymorphisms are Associated with PSA Level, Gleason Score and Prostate Cancer Risk in African-American Men. *Anticancer Research.* 2015; 35:1549–58.
- [28] Ginting RNA, Anggraini DR, Sitorus MS. Vitamin D Receptor Immunoexpression in Benign and Malignant Prostate Tumors. *Open Access Maced J Med Sci.* 2020 Oct 19; 8(B):949–51. doi: 10.3889/oamjms.2020.5148.

- [29] Erida Y, Aminah H, Yulianti H, Hernowo BS. Reseptor Vitamin D (VDR) dan *phosphatidylinositol 3 kinase* (PI3K) secara Independen Memengaruhi Diferensiasi Adenokarsinoma Kolorektal. *Jurnal Farmasi Klinik Indonesia*. 2015;4(4):264-74. doi: 10.15416/ijcp.2015.4.4.264.
- [30] Aminah H, Erida Y, Yulianti H, Hassan AH. Korelasi Ekspresi Reseptor Vitamin D (VDR) dengan Derajat Diferensiasi dan Stadium Adenokarsinoma Kolorektal. *MKB*. 2016;48(2):123-8.
- [31] Kure S, Noshu K, Baba Y, Irahara N, Shima K, Ng K, Meyerhardt JA, *et al.* Vitamin D Receptor Expression is Associated with PIK3CA and KRAS Mutations in Colorectal Cancer. *Cancer Epidemiol Biomarkers Prev*. 2009;18(10):2765-72.

AUTHORS

First author- dr. Zuhri Madriah, Resident of the Department of Anatomical Pathology, Faculty of Medicine, Universitas

Sumatera Utara, Medan, Indonesia, **email ID:** zuhrimardiah@gmail.com

Second Author- Dr. dr. T. Ibnu Alferally, M.Ked (PA) Sp.PA, D.Bioeth. Department of Anatomical Pathology, Faculty of Medicine, Universitas Sumatera Utara, Medan, Indonesia.
The third author- Dr. dr. Delyuzar, M.Ked (PA), Sp.PA (K), Department of Anatomical Pathology, Faculty of Medicine, Universitas Sumatera Utara, Medan, Indonesia.

Correspondence Author- dr. Jessy Chrestella, M.Ked (PA) Sp.PA (K) Department of Anatomical Pathology, Faculty of Medicine, Universitas Sumatera Utara, Medan, Indonesia, email ID:jes_ch@msn.com