# Evolution of Chest CT findings in patients with COVID-19 pneumonia: A retrospective study of the new Pandora's box from Morocco

**Hind Guerroum, Jihane Habi, Meriem Kassimi, Nabil Chikhaoui and Mohamed Mahi.**

Department of Radiology, Faculty of Medicine, Mohammed VI University of Health Sciences (UM6SS)

Cheikh Khalifa international university Hospital, Casablanca, Morocco.

DOI: 10.29322/IJSRP.10.07.2020.p10393
http://dx.doi.org/10.29322/IJSRP.10.07.2020.p10393

***Abstract-***
**Objectives**
To describe the imaging features of hospitalized patients with confirmed COVID-19 infection.
To analyze the evolvement patterns of chest CT images.
**Methods:** A retrospective study of initial chest CT imaging findings of 34 confirmed patients admitted to our university hospital, between 23 March and 23 April 2020. A follow-up chest CT was performed to analyze the evolvement manifestations of initial CT imaging findings.
**Results:** Initial and follow-up chest CT images were collected and analyzed. M/F ratio 24/10. The mean age was 55,11±12.8 years. The predominant imaging feature was ground-glass opacification in 30(88%) patients, crazy paving pattern in 18(53%) patchy consolidation in 18(53%) patients, fibrous stripes 16(47%) patients.
The follow-up chest CT examination was performed in 11 from 34 patients (average of 5-8 days). The progression of the lesions was found in 7(64%) patients, including the increasing and the consolidation of ground-glass opacification besides the appearance of crazy paving patterns, and the fibrous stripes. 2(6%) patients presented absorbed lesions. Initial normal chest CT remains normal in one patient, and ground glass nodule appeared in the RUL in one patient.
The second follow-up CT-scan, performed in 3(38%) patients, showed also a progression of the previous lesions in 2 patients, and absorption of the RUL's ground-glass nodule in one patient.
**Conclusion:** Chest CT has a key role to play in both diagnosis and follow-up of patients with COVID-19 pneumonia. The imaging features are multiple and can change quickly allowing the evaluation of the severity of this infection.
**Highlights:**
- Chest High-resolution CT (HRCT) plays a key role in both the diagnosis and follow-up of patients with COVID-19 pneumonia.
- The imaging features are multiple and can change quickly allowing the evaluation of the severity of this infection.

***Index Terms***- COVID-19; Tomography, X-Ray Computed; Thorax; Pneumonia

## I. Introduction

The outbreak of the 2019 novel coronavirus (2019-nCoV) was first discovered in Wuhan, Hubei province in December 2019. (1) The WHO declared the COVID-19 as a pandemic on March 11, 2020. Since, the disease has spread rapidly across the world causing a global health emergency. (2) As of June 14, 2020, there are more than two million confirmed cases worldwide, including 8.734 cases in Morocco with a cumulative death toll of 212 case. The Coronavirus Disease 2019 (COVID-19), also known as "severe acute respiratory syndrome coronavirus 2" (SARS-CoV-2) is a different branch from the deadly severe acute respiratory syndrome virus 'SARS-CoV' identified in 2003 and the Middle East respiratory syndrome virus MERS-CoV found in 2012.(13) The confirmation of the diagnosis of 2019-nCoV infection requires viral nucleic acid testing in throat swabs, using reverse transcriptase polymerase-chain-reaction (RT-PCR) technology which specificity is high, but sensitivity is low. (3, 4) High-resolution chest CT (HRCT), being highly sensitive (98%) compared to RT-PCR (71%) (3), has a key role to play in both the diagnosis and the evaluation of disease severity, in order to help clinicians in the rapid management of COVID-19 pneumonia.
We aim to describe the imaging features of 34 hospitalized patients with confirmed COVID-19 infection in Casablanca and to analyze their temporal imaging changes.
To the best of our knowledge, this is the first African study on temporal evolution of Chest CT findings in patients with COVID-19 pneumonia.

## II. RESEARCH ELABORATION

This study was approved by the Ethics committee of Cheikh Khalifa international university Hospital. Signed informed consent was exempted since patient information was anonymized to ensure privacy.

**Population and Examination methods**

A retrospective study of initial chest CT imaging findings of 34 confirmed patients admitted to our university hospital, between 23 March 2020 and 23 April 2020.

The inclusion criteria were as follows:

-A nucleic acid testing (NAT) using reverse-transcriptase polymerase-chain-reaction (RT-PCR) was positive in all patients.

-The first High-resolution CT (HRCT) (GE) of the chest was performed after admission to the university hospital of Cheikh Khalifa in Casablanca.

A common chest protocol was followed: A supine position of the patient, arms raised, and a breath-holding during acquisition, including the whole lung volume. layer thickness ranged at 2–5 mm.

All patients wore masks. The machine and the room were completely disinfected after each CT chest examination.

-The follow-up chest CT was performed in 11 patients to analyze the evolvement manifestations of initial CT imaging findings.

**Qualitative image analysis**

Analysis criteria were the number of affected lobes, the location of the lesions, and the main chest CT features specially ground-glass nodules (GGO), crazy paving patterns, patchy consolidation, and fibrous stripes.

**Statistical analysis**

Statistical analysis was performed on SPSS 17.0 (IBM Corporation). Measuring data were expressed as numbers and percentage.

## III. RESULTS AND FINDINGS

**Demographics**

CT images of 34 confirmed patients were collected. M/F ratio: 24/10, mean age was 55,11 ± 12.8 years.

**CT images analysis**

Initial chest CT images were collected and analyzed. 2 (6%) patients had a normal initial chest CT's, 29 (85%) patients had lesions localized in the peripheral lung. Only one lobe was involved in 9 (20%) patients, however all lobes were involved in 7 (26 %) patients. Most of the analyzed lesions were seen in the right lower lobe in 27 (79%) patients, followed by left lower lobe in 26 (76%) patients, 13 (38%) patients showed equal distribution between the left upper lobe and the right middle lobe whilst the right upper lobe has the lowest involvement (12 patients 35%). The predominant imaging feature is of ground-glass opacification in 30 (88%) patients, 18 (53%) patients had a crazy paving lesion, 18 (53%) patients had a patchy consolidation, and 16 (47%) patients had fibrous stripes (Fig 2). Pleural effusions were observed in one case (Fig 1). (Table.1)

Fig 1: CT scans in a 65-year-old man with COVID-19 pneumonia showed pleural effusion (the patient died later)

Table 1: Initial chest CT images

| Number of affected lobes | Patients (n = 34) |
|---|---|
| 1 lobe | 9 (20%) |
| 5 lobes | 7 (26 %) |
| | |
| Lobar involvement | |
| RUL | 12 (35%) |
| RML | 13 (38%) |
| RLL | 27 (79%) |
| LUL | 13 (38%) |
| LLL | 26 (76%) |
| | |
| CT Chest patterns | |
| GGO | 30 (88%) |
| Crazy paving pattern | 18 (53%) |
| Patchy consolidation | 18 (53%) |
| fibrous stripes | 16 (47%) |
| Pleural effusion | 1 |
| No abnormal findings | 2 |
| | |
| Distribution of the Lesions | |
| Peripheral | 29 (85%) |
| Both Peripheral and Perihilar | 12 (35%) |
| | |

RLL= right lower lobe LLL= left lower lobe
LUL= left upper lobe RML= right middle lobe RUL= right upper lobe

The follow-up chest CT examination was performed in 11 patients from 34 patients after 5 8 to days, The progression of the lesions was found in 7 (64%) patients, including the increasing of ground-glass opacification and the consolidation besides the appearance of crazy paving patterns, and the fibrous stripes (Fig 3, 4). 2(6%) patients presented absorbed lesions. (Fig 2) Initial normal chest CT remains normal in one patient, and ground glass nodule appeared in the RUL in one patient (Fig 5)

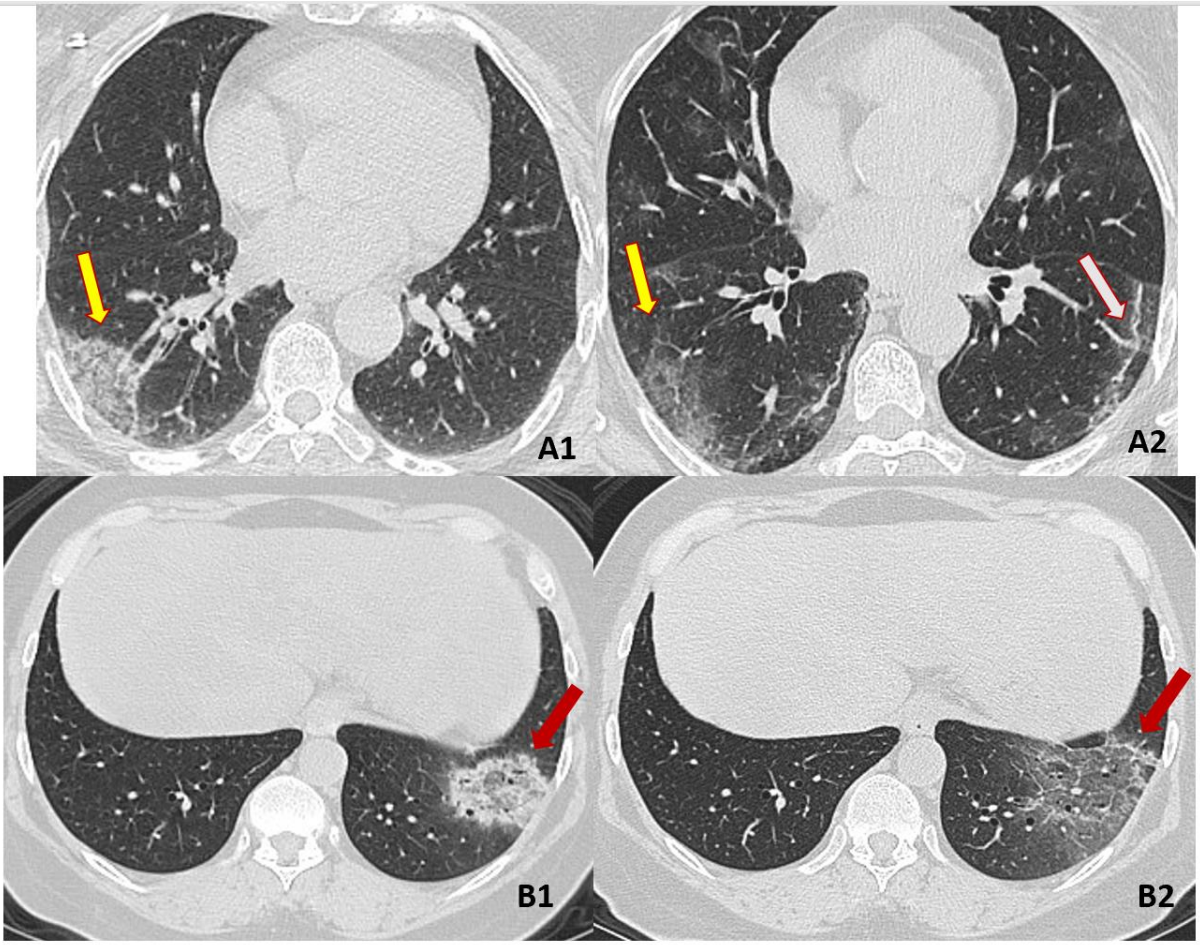


Fig 2: (A1,2) Series CT scans in a 65-year-old woman with COVID-19 pneumonia.
(A1) Scan performed on illness days 3 showed ground-glass opacity with intralobular septal thickening (crazy-paving pattern) in the right lower lobe. (yellow arrow) (A2) Scan obtained on illness days 12 showed that the extent of the ground glass opacity increases, and the density decreases in the right lower lobe (yellow arrow) besides the appearance of the fibrous stripes in the left lower lobe. (white arrow)

(B1,2) Series CT scans in a 60-year-old woman with COVID-19 pneumonia. (B1) Scan obtained after 3 days of illness showed a consolidation in the left lower lobe (Red arrow). (B2) Scan obtained after 7 days of illness showed that the extent of the ground glass opacity increases, and the density decreases, with appearance of intralobular septal thickening (crazy-paving pattern) (Red arrow).

The second follow-up chest CT scan, was performed in 3 (38%) patients from 11 patients, showed also a progression of the previous lesions in 2 patients, (Fig 3, 4) and absorption of ground glass nodule located in the RUL in one patient. (Fig 5)

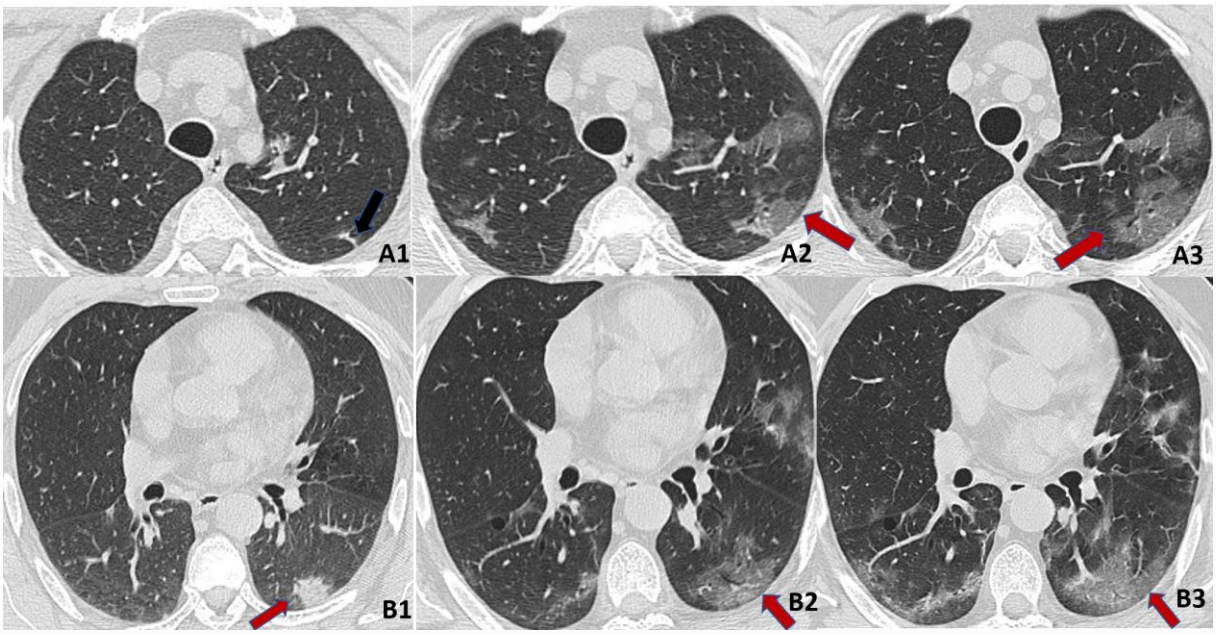


Fig 3: Series CT scans in a 65-year-old man with COVID-19 pneumonia.
(A1, B1) Scan obtained on illness days 3 showed CT scan shows consolidation in the left lower lobe subpleural area (Red arrow) and in left upper lobe besides a fibrous stripe (black arrow)
(A2, B2) Scan obtained on illness days 7 showed consolidation in the left lower lobe progressed to ground glass patches (B2; Red arrow) and appearance of ground glass patches in left upper lobe (A1; Red arrow)
(A3,B3) Scan obtained on illness days 14 showed that the extent of the ground glass patches increased in all lobes, correlated to the clinical deterioration.

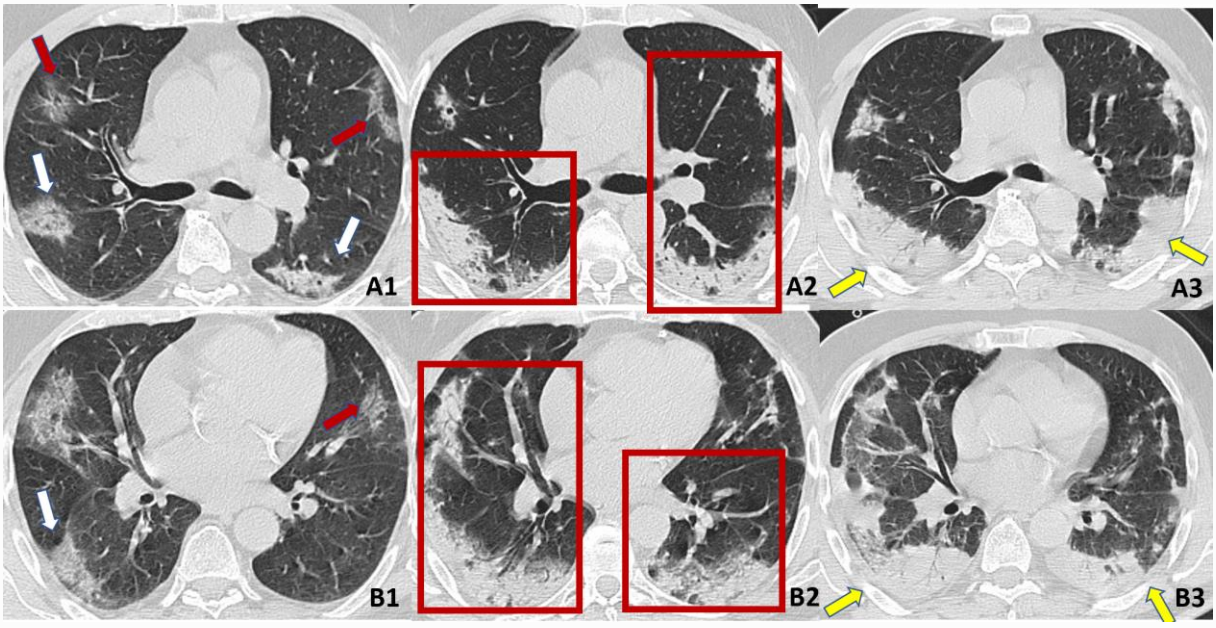


Fig 4: Series CT scans in a 62-year-old man with COVID-19 pneumonia.
(A1, B1) Scan obtained on illness days 3 showed ground-glass opacity in both left upper lobe and right middle lobe (red Arrow) and consolidation in right and left lower lobes. (white Arrow)
(A2, B2) Scan obtained on illness days 15 showed GGO progressed to ground glass patches and consolidation in multi-lobes (Red Boxes)
(A3, B3) Scan obtained on illness days 26 showed that the density and the extent of consolidation increased, (Yellow arrow) correlated to the clinical deterioration


Fig 5**:** Follow up of chest CT findings in a 60-year-old man with COVID-19 pneumonia: First scan was normal **(A).** The second follow up after 10 days of illness showed a ground-glass nodule in the right upper lobe **(B)** (Red arrow). The third follow up after 15 days of illness showed absorption of the ground glass nodule (C) (Red arrow)

## IV. DISCUSSION

COVID-19 is a single-stranded RNA virus, belonging to the same virus family of SARS and MERS, with similar imaging manifestations. It spreads from human to human, through respiratory droplets and contact, with a high incidence and a rapid extent of infection, threatening the global health. (5,6,7) Chest HRCT has an important role in preclinical detection of the COVID 19 pneumonia with high sensitivity allowing a quick diagnosis. This north African study enrolled 34 confirmed SARS-CoV-2 pneumonia patients' chest CT to analyze their imaging initial features, and to study the temporal imaging changes in 11 patients.

According to Pinggui Lei, (15) several studies proved that the chest CT is perfectly capable to detect the typical pulmonary lesions of SARS-CoV-2, especially ground glass opacities (GGO) and consolidation, at the first week after symptom onset, which was demonstrated in our study.
The predominant pattern in our study was ground-glass opacity (88%), as the study of Heshui Shi (17) followed by consolidation in 53% versus 47% found in Shang Wan MD et al. (18) Our results concerning the crazy paving patterns were superior to literature as we found it in 53% versus 19.5% in Vineeta Ojha, (2) and 36.1% in Kunhua Li et al. The paving patterns can be related to the virus-induced diffuse alveolar wall injury, vascular congestion, and alveolar septal inflammation. (7)

Most of the analyzed lesions were seen in the right lower lobe similar to results found in Heshui Shi (17) and Vineeta Ojha. (2) CT features of 2019-nCoV infection presented a predominantly peripheral distribution, with 85% versus 67% found in Shang Wan et al.

In one patient, pleural effusion was observed, which is a poor prognostic indicator in patients infected with MERS-CoV according to previous studies (8) the patient died later.

The follow-up chest CT examination was performed in 11 patients from 34 patients after 5 to 8 days. It showed progression of the lesions in 64%, the extent and the density of ground-glass opacification mixed with the consolidation increased in both lungs in the sub-pleural area, which is consistent with Y.Pan and al (6). Pinggui Lei's (15) also noted that the consolidation or GGO mixed consolidation increased with increasing the stages of COVID-19 pneumonia. This temporal changing imaging could be explained by the replacement of alveoli by exudates or products of other diseases due to the alveolar wall collapse. (7)
The pulmonary lesions were absorbed in 6%, with the appearance of the fibrous stripe correlated to clinical improvement. As reported by Y.Pan and al (6)

A third follow-up chest CT scan was performed in 3 patients (28%) showed also a progression of the previous lesions in 2 patients as they were clinically deteriorated, and absorption of ground glass nodule located in the RUL in one patient, as its clinical condition improved.

Our study showed that the evolution of Chest CT findings is very rapid;
A focal GGO becomes a diffuse bilateral GGO or GGO with consolidation within 1–3 weeks, which is consistent with the literature. (15)

Follow up chest CT allows the monitoring of disease changes, by showing either the progression or improvement of the radiological features, in order to help clinicians in the rapid management of COVID-19 pneumonia.

The limitations of our study were as follows: First, the study was retrospective. Second, a small sample size was enrolled. We propose that a quantitative study of different pneumonia lesions should be considered in the future to compare initial CT features and temporal imaging changes to evaluate disease severity, and a long-term follow-up study is required in the future to evaluate lung fibrosis and the impact of COVID-19 pneumonia on patients' lung function.

## V. CONCLUSION

The predominant pattern of COVID-19 Pneumonia in chest CT scans were a bilateral, subpleural, ground-glass opacities, mostly localized in the right lower lobe.
The images change rapidly following a specific pattern, within 1–3 weeks, whether it was a significant progress or absorption.
HRCT plays an important role in both the diagnosis and the evaluation of disease severity.

## ACKNOWLEDGMENT

We thank Pr Mohamed Khalis Phd (International School of Public Health, Mohammed VI University of Health Sciences, Hospital, Casablanca, Morocco) for support.

## REFERENCES

[1] Nadia nathan, Blandine Prevost, Harriet Corvolth, Atypical presentation of COVID-19 in young infants The lancet April 27,2020

[2] Vineeta Ojha1 & Avinash Mani2 & Niraj Nirmal Pandey1 & Sanjiv Sharma1 & Sanjeev Kumar1 CT in coronavirus disease 2019 (COVID-19): a systematic review of chest CT findings in 4410 adult patients European radiology 2020

[3] Yicheng Fang 1, Huangqi Zhang 1, Jicheng Xie 1, Minjie Lin 1, Lingjun Ying 1, Peipei Pang 1, Wenbin Ji Sensitivity of Chest CT for COVID-19: Comparison to RT-PCR Radiology 2020 Feb

[4] Tan W, Zhao X, Ma X et al (2020) A novel coronavirus genome identified in a cluster of pneumonia cases- Wuhan, China 2019−2020. China CDC Weekly 2:61–62.

[5] Chan JF, Yuan S, Kok KH et al (2020) A familial cluster of pneumonia associated with the 2019 novel coronavirus indicating person-to-person transmission: a study of a family cluster. Lancet S0140-6736(20)30154–30159

[6] Y., Guan, H., Zhou, S. et al. Initial CT findings and temporal changes in patients with the novel coronavirus pneumonia (2019-nCoV): a study of 63 patients in Wuhan, China. Eur Radiol (2020).

[7] Li, X., Zeng, W., Li, X. et al. CT imaging changes of corona virus disease 2019(COVID-19): a multi-center study in Southwest China. J Transl Med 18, 154 (2020).

[8] Das KM Lee EY Enani MA et al. CT correlation with outcomes in 15 patients with acute Middle East respiratory syndrome coronavirus. AJR Am J Roentgenol. 2015; 204: 736-742

[9] Qiongjie Hu, Hanxiong Guan Ziyan Sun Lu Huang Chong Chen Tao Ai Yueying Pan Liming Xia Early CT features and temporal lung changes in COVID-19 pneumonia in Wuhan, China Eur Radiol (2020)

[10] Ming-Yen Ng, Elaine YP Lee, Jin Yang, Fangfang Yang, Xia Li, Hongxia Wang, Macy Mei-sze Lui, Christine Shing-Yen Lo, Barry Leung, Pek-Lan Khong, Christopher Kim-Ming Hui, Kwok-yung Yuen, Michael David Kuo Imaging Profile of the COVID-19 Infection: Radiologic Findings and Literature Review Radiology 2020

[11] Zhang, R., Ouyang, H., Fu, L. et al. CT features of SARS-CoV-2 pneumonia according to clinical presentation: a retrospective analysis of 120 consecutive patients from Wuhan city. Eur Radiol (2020)

[12] Yuhui Wang, PhD, Chengjun Dong, MD, Yue Hu, PhD, Chungao Li, MD, Qianqian Ren, MD, Xin Zhang, MD, Heshui Shi, PhD, Min Zhou, PhD, Temporal Changes of CT Findings in 90 Patients with COVID-19 Pneumonia: A Longitudinal Study Radiology 2020

[13] Zhu N, Zhang D, Wang W, Li X, Yang B, Song J, Zhao X, Huang B, Shi W, Lu R, et al. A Novel coronavirus from patients with pneumonia in China, 2019. New England Journal Med. 2020;382:727–33.

[14] Xu Y-H, Dong J-H, An W-M et al (2020) Clinical and computed tomographic imaging features of novel coronavirus pneumonia caused by SARS-CoV-2. J Infect 80(4):394–400

[15] Lei P, Fan B, Yuan Y (2020) The evolution of CT characteristics in the patients with COVID-19 pneumonia. J Infect. 2020 Mar 19 [cited 2020 Mar 27];0(0) Available from: https://www. journalofinfection.com/article/S0163-4453(20)30143-2/abstract

[16] Pan F, Ye T, Sun P, Gui S, Liang B, Li L, et al. Time course of lung changes on chest CT during recovery from 2019 novel coronavirus (COVID-19) pneumonia. [Published online ahead of print, 2020 Feb 13]. Radiology 2020:200370. doi:10. 1148/radiol.2020200370.

[17] Shi H, Han X, Jiang N, Cao Y, Alwalid O, Gu J, et al. Radiological findings from 81 patients with COVID-19 pneumonia in Wuhan, China: a descriptive study. [Published online ahead of print, 2020 Feb 24]. Lancet Infect Dis 2020. doi:10.1016/S1473-3099(20)30086-4.

[18] Shang Wan MD , Mingqi Li MD , Zheng Ye MD , Caiwei Yang MD , Qian Cai MD , Shaofeng Duan PhD , Bin Song MD , CT manifestations and clinical characteristics of 1115 patients with coronavirus disease 2019 (COVID-19): A systematic review and meta-analysis, Academic Radiology (2020), doi: https://doi.org/10.1016/j.acra.2020.04.033

[19] Li K, Wu J, Wu F, Guo D, Chen L, Fang Z, Li C. The Clinical and Chest CT Features Associated With Severe and Critical COVID-19 Pneumonia. Invest Radiol. 2020 Jun;55(6):327-331. doi: 10.1097/RLI.0000000000000672.

[20] Huang C, Wang Y, Li X et al (2020) Clinical features of patients infected with 2019 novel coronavirus in Wuhan, China. Lancet S0140-6736(20)30183–30185

## AUTHORS

**First Author** – Hind GUERROUM, MD Department of Radiology, Faculty of Medicine, Mohammed VI University of Health Sciences (UM6SS) Cheikh Khalifa international university Hospital, Casablanca, Morocco. guerroumhind@gmail.com

**Second Author** – Jihane HABI, MD (habijihane@gmail.com) and Mariam KASSIMI, MD, (M.Kassimi91@hotmail.com ).

**Third Author** – Nabil Chikhaoui ,MD ( Nabil_chikhaoui@yahoo.fr ) and Mohamed Mahi , MD, (Prmahimohamed@yahoo.fr )

**Correspondence Author** – Hind GUERROUM, MD guerroumhind@gmail.com, hguerroum@um6ss.ma