

PCA3 Blood Level Correlates Positively with Prostate Non Contrast Multiparametric MRI Score

Tjondro Setiawan¹, Bachtiar Murtala², Andi Fachruddin Benyamin³, Mochammad Hatta⁴, Ali Suyono Purwita⁵, Taufan Tenggara⁶, Egi Edward Manuputty⁷, Gatot Susilo Lawrence⁸

¹. Radiology Department, Gading Pluit Hospital-Jakarta, tjondrosetiawan@gmail.com

². Radiology Department, Hasanuddin University-Makassar, bach_murtala@yahoo.com

³. Internal Medicine Department, Hasanuddin University-Makassar, andifach@yahoo.co.id

⁴. Microbiology Department, Hasanuddin University-Makassar, hattaram@indosat.net.id

⁵. Urology Department, Pluit Hospital-Jakarta, dr_ali_suyono@yahoo.co.id

⁶. Urology Department, Gading Pluit Hospital-Jakarta, tenggara@cbn.net.id

⁷. Urology Department, Gading Pluit Hospital-Jakarta, ee_manuputty@yahoo.com

⁸. Pathology Anatomy Department, Hasanuddin University-Makassar, gatot.law@gmail.com

Abstract- Background and Purpose: Prostate Cancer Antigen 3 (PCA3) and Multi parametric Magnetic Resonance Imaging (mp-MRI) are promising tools for prostate cancer detection. As the most specific marker for prostate cancer, PCA3 had been studied and proved its use fullness in detecting prostate cancer, it is over expressed in prostate cancer. The capability of multi parametric acquisition in MRI improves detection rate. Molecular alteration happens prior to morphological change, both modalities utilize molecular changes as an early sign of prostate cancer. This research will study the correlation between PCA3 as molecular marker in blood with non contrast mp-MRI score also Apparent Diffusion Coefficient (ADC) value as molecular imaging.

Method: There were 68 patients enrolled and met inclusion also exclusion criteria. All patients underwent mp-MRI and blood withdrawal procedure. Evaluation of non contrast mp-MRI category was based on Prostate Imaging Reporting and Data System (PIRADS) version 2, while PCA3 was quantified for mRNA level using Real Time Polymerase Chain Reaction (RT-PCR). Correlation test was done between PCA3, mp-MRI score also ADC.

Results: PCA3 has positive fair correlation with mp-MRI ($r=0.404, p=0.001$), negative fair correlation with ADC ($r=-0.373, p=0.002$). There is strong negative correlation between mp-MRI score and ADC ($r=-0.882, p=0.000$).

Conclusion: Higher level of PCA3 that is over expressed in prostate cancer correlates with bigger total score of non contrast mp-MRI and lower ADC value. As mp-MRI score gets higher, the ADC value also will get lower.

Index Terms- PCA3 – mpMRI score – ADC – prostate cancer – correlation

I. INTRODUCTION

Prostate Cancer Antigen 3 (PCA3) is the most specific marker for prostate, which is over expressed in prostate cancer. It can be detected in prostate tissue, urine, and blood. As a long non coding RNA, it is not expressed as protein and only can be detected in RNA form (Bussemakers *et al.*, 1999; De Kok *et al.*,

2002; Ferreira *et al.*, 2012; Neves *et al.*, 2013; Malik and Feng, 2016).

PCA3 had been studied and proved its usefulness in detecting prostate cancer, United States Food and Drug Administration (US FDA) had recognized commercial kit for PCA3 urine test. Molecular alteration happens prior to morphological change, both mp-MRI and PCA3 is promising for prostate cancer detection. Taken into consideration about how some patients might feel uncomfortable during prostate massage that is done prior to urine sample collection, PCA3 blood test could be more feasible to be done routinely. Since early detection should avoid unnecessary procedure that could add more burdens to patients, mp-MRI in this research will be done without contrast injection. Previous study had found significant correlation between PCA3 urine test and mp-MRI (Leyten *et al.*, 2013). Multi parametric MRI includes anatomical imaging T2 Weighted Images (T2WI) with functional imaging such as Diffusion Weighted Imaging (DWI), Dynamic Contrast-Enhanced (DCE) MRI or Magnetic Resonance Spectroscopic Imaging (MRSI) in order to achieve better sensitivity also specificity for prostate cancer detection. Since DCE role has been questioned nowadays, with no clear evidence that it improves detection performance compared with the combination of T2WI and DWI, also MRSI has not proven its benefits compared to the interpretation difficulties and technical challenges, this research will use T2WI and DWI sequence with ADC value as a complementary value (National Institute for Health and Clinical Excellence, 2014; Tan *et al.*, 2015; Mohler, Armstrong and Prostate Cancer Panel Member, 2016; Turkbey, I.B., 2017).

This research will study correlation between PCA3 as molecular marker in blood with non contrast mp-MRI total score also Apparent Diffusion Coefficient (ADC) value as molecular imaging. Until now, authors have not been able to find other previous research that correlates blood PCA3 with non-contrast mp-MRI total score and ADC, when it is important in the light of the increasing role of non contrast mp-MRI for prostate cancer detection.

II. METHODS

All patients underwent mp-MRI procedure using single calibrated MRI unit 1.5 Tesla (Avanto Fit), gradient strength 45 mT/m, slew rate 200 T/m/s, with parameter and specifications as described in table 1.

An endorectal prostate coil (Sentinelle Medical, Siemens AG) was inserted using analgesic gel, a pelvic surfaced array coil is also used. T2WI and DWI categories are scored according to

Prostate Imaging-Reporting and Data System (PIRADS) version 2. ADC value was acquired by setting Region of Interest (ROI) in the specific area in the DWI sequence. ADC value would automatically generated by the MRI program, the error in placing the ROI would cause an error for the value as well. To use the same ADC reference value from this research, one should adapt the same specification of MRI as mentioned in table 1.

Table 1. Parameter of mp-MRI

No	Sequence and imaging plane	Sequence type	TR (msec)	TE (msec)	Field of View (mm)	Matrix	In-Plane Resolution (mm ²)	Slice Thickness (mm)	Flip Angle (degree)	Average/ b value	Slice Spacing (mm)	Phase Encoding Direction	Scan Duration (min:sec)
1	T2-weighted												
	Axial	Turbo Spin Echo	7000	112	160	330 x 384	0.4 x 0.4	4	160	2	0	R-L	3:39
	Coronal	Turbo Spin Echo	7000	98	160	298 x 320	0.5 x 0.5	4	160	2	0	R-L	2:57
	Sagittal	Turbo Spin Echo	7000	119	160	266 x 320	0.5 x 0.5	4	160	2	0	H-F	2:57
2	DWI												
	Axial	Echo Planar Spin Echo	3600	86	200	48 x 140	1.4 x 1.4	4	-	0, 50, 500, 800, 1000, 1500, 2000	0	R-L	9:16

TR, repetition time; TE, echo time; DWI, Diffusion Weighted Imaged; msec, millisecond; mm; millimeter; min, minute; sec, second; R, Right; L, Left; H, Head; F, Feet

Peripheral blood was withdrawn and directly put in EDTA tube for nucleotide extraction followed by DNA amplification with primers Forward 5'-TATTCTGAAGTCAGAGTGTCCAG-3' and primer Reverse:5'-CTTATTTCTCACCTCTGTATCATCAGG-3' with housekeeping gene b2MF:5-GTCTTTCTATCTCTTGTACTACTGAA-3 and b2MR: 5 – AACTATCTTGGGCTGTGACAAAG -3 using Qiagen SYBR-GREEN qPCR Mastermix (QIAGEN, Germany). Each reaction contained 7.5 ml of qPCR mastermix, 5 pM of each forward and reverse primer and 5 ml of the diluted cDNA template. The following cycling conditions were applied: 95°C for 15 minutes, followed by 45 cycles of 95°C for each 20 seconds period, 58–59°C for 20 seconds and 72°C for 20 seconds. Data for each cycle was acquired at the elongation step and each reaction was carried out in triplicate. Relative gene expression levels were calculated using Pfaffl calculation (Pfaffl, 2001).

III. RESULTS

There were 68 patients who participated in this study. Inclusion criteria are PSA level ≥ 4 ng/ml with or without nodular palpable prostate from DRE. Exclusion criteria are hypoglycemia, hyponatremia, deviant temperature, not cooperative/ fail to do MRI procedure, patients with MRI contra indications, claustrophobia. All of them underwent mp-MRI: T2WI and DWI sequence exam also blood withdrawal to be evaluated for PCA3.

Table 1. Patients' Results

No	Description	Number/ percentage
1.	Sample number	68
2.	Mean age	67.72 ±1.036
3.	Median of PSA	10.3 (4.46:110.69)
4.	Median of PCA3	9.572 (6.070:14.097)
5.	Median of mp-MRI score	5 (2:10)
6	Median of ADC value	0.792 (0.339:1.868)

PCA3 could be detected from all the blood samples that were collected. The median value is 9.572 with the minimum value is 6.070 and maximum value is 14.097.

Multi parametric MRI has total score of 2 until 10, with the median value is 5. ADC value has median value of 0.792, minimal value is 0.339 while maximum value is 1.868.

Correlation of PCA3 Levels With Multi parametric MRI Total Score

Numeric variables of PCA3 levels were analyzed statistically using nonparametric Spearman correlation. There was statistically significant fair correlation between PCA3 level and total score of mp-MRI (R=0.404, p=0.001). Figure 1 below showed scattered plots of linear correlation between PCA3 levels and mp-MRI total score.

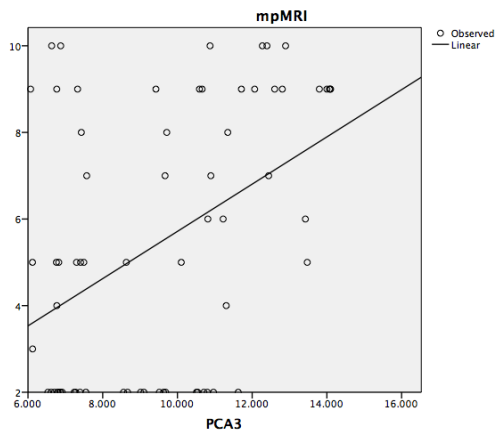


Figure 1. Correlation curve of PCA3 and mp-MRI score

Correlation of PCA3 Levels With ADC

PCA3 levels had statistically inverse significant correlation with ADC value ($R=-0.373, p=0.002$) as shown in figure 2 below.

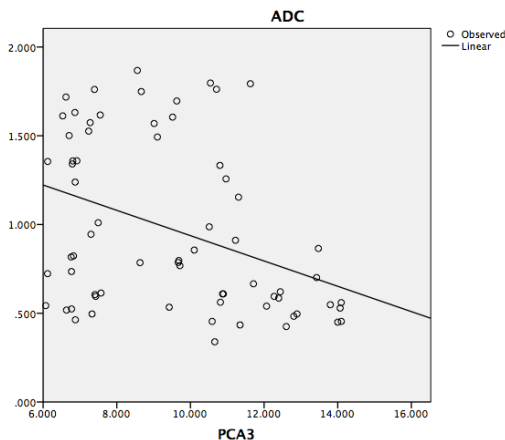


Figure 2. Correlation curve of PCA3 and ADC value

Correlation of Multiparametric MRI Total Score With ADC

Total score of mp-MRI has a strong inverse correlation with ADC value ($R=-0.882, p=0.000$).

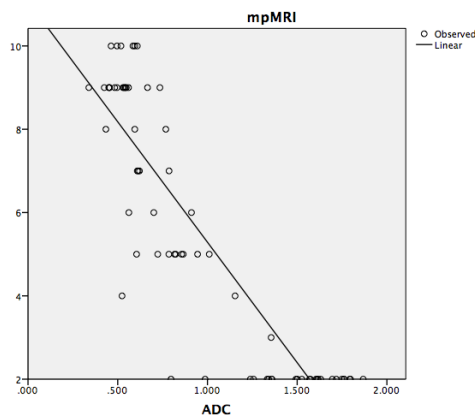


Figure 3. Correlation curve of mp-MRI score and ADC value

IV. DISCUSSION

From the results above, it is shown that PCA3 that's theoretically over expressed in prostate cancer has linear correlation with mp-MRI total score, and inverse correlation with ADC value. The higher expression of PCA3 that indicates malignancy, the higher mp-MRI total score and the lower ADC value should be. The result is also consistent with the strong inverse correlation between mp-MRI score and ADC value. Aiming for better feasibility and comfort for patients, this research use non-contrast mp-MRI exam using T2WI and DWI sequence. From previous research, T2WI and DWI sequence has better Area Under the Curve (AUC) than T2WI alone, and interestingly T2WI alone performed better than T2WI+DCE as well as three sequences combined. This result lead to better sensitivity and specificity for T2WI and DWI for prostate lesion detection in both peripheral also transitional zone (Delongchamps *et al.*, 2010). Meta-analysis study mentioned T2WI and DWI yielded significantly better AUC, sensitivity and specificity than T2WI alone, also superior to DCE alone (Tan *et al.*, 2012).

T2WI remains to be the backbone of any prostate MRI examination due to its ability to delineate zonal anatomy, detect, localize and stage cancer, including assessment for extra-prostatic extension and seminal vesicle invasion.

DWI sequence explores the random Brownian motion of water molecules in body, it studies the displacement of water molecules during the interval between the application of two diffusion sensitizing gradients. In tumor tissues, cellularity generally increases and cell membranes are hydrophobic that act as obstacles or barrier for water molecular movement, therefore result in diffusion restriction (Cornud, 2017). Data obtained from DWI performed at different b values allows for quantitative analysis. The net displacement of water molecules is interpreted as ADC. Use of several b values, as applied in this research will help to improve the fit of the curve and potentially minimize errors in ADC calculation which is automatically done by MR systems. Low ADC values within an area indicates the presence of restricted diffusion (Sato *et al.*, 2005; Cornud, 2017). It is in accordance with initial publication that reported mean ADC value was significantly lower in prostate cancer than in benign tissue. However, the reported ADC values in prostate cancer show great variation, selection of b value is one factor among other that influences the value (Issa, 2002; Cornud, 2017).

Differentiating cancer from benign lesion on the basis of ADC measurement value only is difficult and seems reckless, it requires visual assessment of both the signal intensity on high b value DW image combined with visual assessment of ADC map. When properly optimized, both 1.5 Tesla (T) and 3.0 T magnets can provide adequate diagnostic quality for prostate MRI in clinical practice. The use of rectal coil will also acquire smaller Field Of View (FOV) and thinner slice in 3 T or 1.5 T (Medved *et al.*, 2014).

This research result is expected to encourage further research in blood PCA3 and non-contrast MRI, the level in malignancy and the cut off value, also diagnostic parameters to be compared to PIRADS version 2 .

V. CONCLUSION

PCA3 level correlates with non contrast mp-MRI results, both in total score and ADC value. Mp-MRI score itself has strong correlation with ADC value.

Higher level of PCA3 that is over expressed in prostate cancer correlates with bigger total score of non contrast mp-MRI and lower ADC value. As mp-MRI score gets higher, the ADC value also will get lower.

REFERENCES

- [1] Bussemakers, M. J. G., Van Bokhoven, A., Verhaegh, G. W., Smit, F. P., Karthaus, H. F. M., Schalken, J. A., Debruyne, F. M. J., Ru, N. and Isaacs, W. B. (1999) 'DD3: A new prostate-specific gene, highly overexpressed in prostate cancer', *Cancer Research*, 59(23), pp. 5975–5979. doi: 10.1038/ncb2161.
- [2] Delongchamps, N. B., Rouanne, M., Flam, T., Beuvon, F., Liberatore, M., Zerbib, M. and Cornud, F. (2010) 'Multiparametric magnetic resonance imaging for the detection and localization of prostate cancer: Combination of T2-weighted, dynamic contrast-enhanced and diffusion-weighted imaging', *BJU International*, 107(9), pp. 1411–1418. doi: 10.1111/j.1464-410X.2010.09808.x.
- [3] Ferreira, L. B., Palumbo, A., de Mello, K. D., Sternberg, C., Caetano, M. S., de Oliveira, F. L., Neves, A. F., Nasciutti, L. E., Goulart, L. R. and Gimba, E. R. P. (2012) 'PCA3 noncoding RNA is involved in the control of prostate-cancer cell survival and modulates androgen receptor signaling.', *BMC cancer*, 12(1), p. 507. doi: 10.1186/1471-2407-12-507.
- [4] Issa, B. (2002) 'In vivo measurement of the apparent diffusion coefficient in normal and malignant prostatic tissues using echo-planar imaging', *Journal of Magnetic Resonance Imaging*, 16(2), pp. 196–200. doi: 10.1002/jmri.10139.
- [5] De Kok, J. B., Verhaegh, G. W., Roelofs, R. W., Hessels, D., Kiemeny, L. A., Aalders, T. W., Swinkels, D. W. and Schalken, J. A. (2002) 'DD3PCA3, a very sensitive and specific marker to detect prostate tumors', *Cancer Research*, 62(9), pp. 2695–2698. doi: 10.1016/s0022-5347(01)65160-7.
- [6] Leyten, G. H. J. M., Wierenga, E. A., Michiel Sedelaar, van Oort, I. M., Futterer, J. J., Barentsz, J. O., Schalken, J. A. and Mulders, P. F. A. (2013) 'Value of PCA3 to predict biopsy outcome and its potential role in selecting patients for multiparametric MRI', *International Journal of Molecular Sciences*, 14(6), pp. 11347–11355. doi: 10.3390/ijms140611347.
- [7] Malik, B. and Feng, F. (2016) 'Long noncoding RNAs in prostate cancer: overview and clinical implications', *Asian Journal of Andrology*, 18(4), p. 568. doi: 10.4103/1008-682X.177123.
- [8] Medved, M., Soylyu-Boy, F. N., Karademir, I., Sethi, I., Yousuf, A., Karczmar, G. S. and Oto, A. (2014) 'High-resolution diffusion-weighted imaging of the prostate', *American Journal of Roentgenology*, 203(1), pp. 85–90. doi: 10.2214/AJR.13.11098.
- [9] Mohler, J. L., Armstrong, A. J. and Prostate Cancer Panel Member (2016) *NCCN Clinical Practice Guidelines in Oncology: Prostate Cancer, Prostate Cancer version 3*. doi: 10.1016/B978-0-12-800077-9.00059-1.
- [10] National Institute for Health and Clinical Excellence (2014) *Prostate cancer : diagnosis and management*.
- [11] Neves, A. F., Dias-Oliveira, J. D. D., Araújo, T. G., Marangoni, K. and Goulart, L. R. (2013) 'Prostate cancer antigen 3 (PCA3) RNA detection in blood and tissue samples for prostate cancer diagnosis', *Clinical Chemistry and Laboratory Medicine*, 51(4), pp. 881–887. doi: 10.1515/cclm-2012-0392.
- [12] Pfaffl, M. W. (2001) 'A new mathematical model for relative quantification in real-time RT-PCR.', *Nucleic acids research*, 29(9), p. e45. doi: 10.1093/nar/29.9.e45.
- [13] Cornud, Fr. Diffusion Weighted Imaging of the Prostate. In: MRI of the prostate, A practical approach. Ed: Rosenkrantz, A. B. (2017) *MRI of the Prostate*. Thieme Publishers. chapter 4, p41-48.
- [14] Turkbey, I.B., Sankineni, S., Choyke P.L. Dynamic Contrast-Enhanced MRI of the Prostate. In: MRI of the prostate, A practical approach. Ed: Rosenkrantz, A. B. (2017) *MRI of the Prostate*. Thieme Publishers. chapter 5, p60-69.
- [15] Sato, C., Naganawa, S., Nakamura, T., Kumada, H., Miura, S., Takizawa, O. and Ishigaki, T. (2005) 'Differentiation of noncancerous tissue and cancer lesion by apparent diffusion coefficient values in transition and peripheral zones of the prostate', *Journal of Magnetic Resonance Imaging*, 21(3), pp. 258–262. doi: 10.1002/jmri.20251.
- [16] Tan, C. H., Hobbs, B. P., Wei, W. and Kundra, V. (2015) 'Dynamic Contrast-Enhanced MRI for the Detection of Prostate Cancer: Meta-Analysis', *AJR AM J. Roentgenol*, 204(4), pp. W439-448. doi: 10.2214/AJR.14.13373.
- [17] Tan, C. H., Wei, W., Johnson, V. and Kundra, V. (2012) 'Diffusion-weighted MRI in the detection of prostate cancer: Meta-analysis', *American Journal of Roentgenology*, 199(4), pp. 822–829. doi: 10.2214/AJR.11.7805.

AUTHORS

- First Author** – Tjondro Setiawan, Radiology Department, Gading Pluit Hospital-Jakarta, tjondrosetiawan@gmail.com
Second Author – Bachtiar Murtala, Radiology Department, Hasanuddin University-Makassar, bach_murtala@yahoo.com
Third Author – Andi Fachruddin Benyamin, Internal Medicine Department, Hasanuddin University-Makassar, andifach@yahoo.co.id
Fourth Author – Mochammad Hatta, Microbiology Department, Hasanuddin University-Makassar, hattaram@indosat.net.id
Fifth Author – Ali Suyono Purwita, Urology Department, Pluit Hospital-Jakarta, dr_ali_suyono@yahoo.co.id
Sixth Author – Taufan Tenggara, Urology Department, Gading Pluit Hospital-Jakarta, tenggara@cbn.net.id
Seventh Author – Egi Edward Manuputty, Urology Department, Gading Pluit Hospital-Jakarta, ee_manuputty@yahoo.com
Eight Author – Gatot Susilo Lawrence, Pathology Anatomy Department, Hasanuddin University-Makassar, gatot.law@gmail.com