

Unusual Presentations of Covid-19

Dr. Pratima Goyal *, Dr. Prashant Hiwale **, Dr. Narinder kumar Girdhar ***

DOI: 10.29322/IJSRP.12.04.2022.p12421

<http://dx.doi.org/10.29322/IJSRP.12.04.2022.p12421>

Paper Received Date: 11th March 2022

Paper Acceptance Date: 28th March 2022

Paper Publication Date: 6th April 2022

Abstract- Coronavirus disease (COVID-19) caused by SARS-CoV-2 is a highly infectious disease that primarily affects the respiratory system but is characterised by multisystem involvement of other systems as well. The various reported extrapulmonary and unusual manifestations are neurological complications, hepatic and gastrointestinal complications, renal dysfunction, myocardial injury etc; some of which have been described in this article to shed light on the wide range of clinical spectrum displayed by COVID-19 disease. It has been found that both adaptive and innate immunity is activated in this disease that results in a cascade of inflammatory responses that plays a major role in the multisystem complications caused by the disease. The article also lists the possible mechanisms by which the virus damages various other organs for a deep understanding of the disease process for physician guidance.

Index Terms- COVID-19, unusual, extrapulmonary, myocardial, gastrointestinal.

I. INTRODUCTION

Coronavirus disease (COVID-19) has rapidly emerged as a global pandemic ever since it was first reported in 2019 and is caused by a severe acute respiratory syndrome coronavirus 2 (SARS-CoV-2) which is a betacoronavirus.¹ Although COVID-19 is primarily a respiratory illness with predominant pulmonary symptoms, it has a multisystem involvement with renal, gastrointestinal, cardiac, neurological and haematological manifestations.² In this article we aim to throw light on the atypical presentations of COVID-19 in the form of various extrapulmonary and rare manifestations as witnessed in the patients and understand the underlying pathology of COVID-19 responsible for the changes to contribute to an overall better understanding of this evolving disease.

II. COVID INDUCED PANCREATITIS

Acute pancreatitis is a common gastrointestinal disease requiring immediate hospitalisation and having multiple etiologies.³ Acute pancreatitis is a rare complication of COVID-19. There are multiple case reports citing the occurrence of COVID-19 and acute pancreatitis in patients without any other clear etiology and therefore it is imperative to establish whether or not there is any etiological relationship between acute pancreatitis and COVID-19 or else it could lead to an increase in the incidence of idiopathic pancreatitis in patients with COVID-19.

III. HAEMORRHAGIC PLEURAL EFFUSION IN PANCREATITIS:

Right sided haemorrhagic pleural effusion is a very rare manifestation of pancreatitis since most of the effusions in pancreatitis are reactive and left sided.⁴ We present 2 case reports of patients who developed acute pancreatitis secondary to covid-19 infection and the first case report also presented with right sided haemorrhagic pleural effusion.

CASE 1

First was a 67 year old male, known case of diabetes mellitus and hypertension admitted in our hospital with complaints of fever, cough and dyspnea for 3-4 days. On examination patient had low saturation and crepitations in the chest. Routine workup revealed patient was COVID-19 RT-PCR positive with raised D-dimer (954 ng/ml) and HRCT chest revealed bilateral ground glass opacities with areas of consolidation. Patient was managed with I.V antibiotics, inj Remdesvir, low molecular weight heparin, zinc, vitamin C and oxygen inhalation and soon recovered and was discharged.

However patient presented to us again a month later with complaints of breathing difficulty and cough. On examination there were decreased breath sounds on the right side. Chest X ray revealed massive right side pleural effusion. Hence an ICD tube was inserted on the right side which drained haemorrhagic fluid. Routine workup was sent that revealed low haemoglobin of 9.4mg/dl, TLC-10,800, Platelet-3,57,000. Liver and renal function tests were normal. Pleural fluid analysis revealed : ADA- 23.8 IU/L, Glucose- 89mg/dl, protein- 2.2g/dl, TLC- 700 CELLS (80%-lymphocytes, 20%-polymorphs), no malignant cells and raised fibrin degradation product- 5-10 mcg/ml, RBC +2. Serum LDH was elevated- 1292 IU/L. INR, prothrombin time and D-Dimer values were normal. A contrast CT imaging of the chest was done along with CT pulmonary angiography (to rule out pulmonary embolism) which revealed- right sided pleural effusion with adjacent atelectatic changes and few pre, paratracheal, subcarinal lymph nodes were seen (subcentimetric in size) along with changes of **acute pancreatitis**. No pulmonary thrombo-embolism was seen in the imaging. A covid-19 antibody test was done that came positive : 11.6. No other etiologies leading to acute pancreatitis were found. Patient was non alcoholic and no gall stones were found on imaging along with normal triglyceride levels. Patient was managed with conservative treatment and ICD tube was removed and patient discharged in stable condition.



FIGURE 1 : HAEMORRHAGIC PLEURAL FLUID DRAINED VIA ICD TUBE

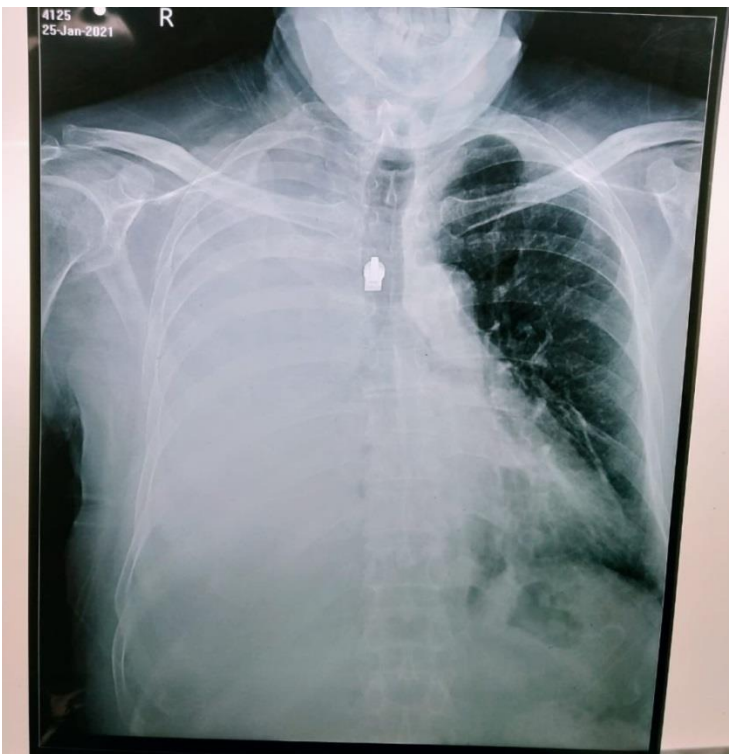


FIGURE 2

CASE 2

The 2nd patient was a 29 year old male patient who came with complaints of fever, cough and dyspnea for 1 week. He had low SpO₂ at presentation and was given oxygen support, rest of the vitals were stable. Patient tested positive for COVID-19 RT PCR. Routine tests revealed raised urea-122mg/dl, creatinine-1.17

mg/dl, total bilirubin 8.28mgdl, direct bilirubin- 7.03mgdL, LDH 2,229 U/L, CRP –reactive, high TLC 21,900. Patient also started complaining of pain abdomen with multiple episodes of vomiting. On testing he was found to have raised serum amylase(87 UL) and lipase(153 U/L) suggestive of pancreatitis. An ultrasound whole abdomen was done that did not reveal any gall stones or biliary

pathology and patient did not consume alcohol. Patient was treated conservatively on the lines of covid-19 infection and pancreatitis with I.V antibiotics, low dose steroids, enoxaparin, zinc and vit C , IV fluids and pain killers. After 4-5 days blood tests improved: total bilirubin- 1.88, direct bilirubin- 1.01, SGOT- 112, SGPT- 174 LDH- 408, TLC-9000, urea-53, creatinine 0.89. Patient also improved symptomatically and was discharged in stable condition.

IV. MYOCARDIAL ISCHEMIA AND COVID-19

Covid-19 is associated with cardiac manifestations like myocardial injury, acute coronary syndromes and myocarditis.⁵ Incidence of arterial and venous thromboembolic events predisposing to myocardial infarction and stroke are also commonly reported with COVID-19. Here we present a case of patient with confirmed COVID-19 who developed signs of myocardial ischemia.

CASE 3

61 year old male patient, known hypertensive and past history of stroke (patient was not on any antiplatelet drugs) many years ago, presented with complaints of dyspnea, cough and low oxygen saturation on presentation. Patient tested positive for COVID-19 RT-PCR and was managed with oxygen support, I.V antibiotics, anticoagulants, steroids, zinc and multivitamins. Investigations revealed normal blood counts, liver and renal function tests. CRP was reactive. Patient's initial electrocardiogram was normal but subsequent ECG revealed 'T' wave inversions in lead 1 and avL which suggested ongoing myocardial ischemia. Trop- I was done that was negative and patient started on low dose tablet ecosprin and statins. Subsequent ECG done showed resolution of 'T' wave inversions and restoration of sinus rhythm.

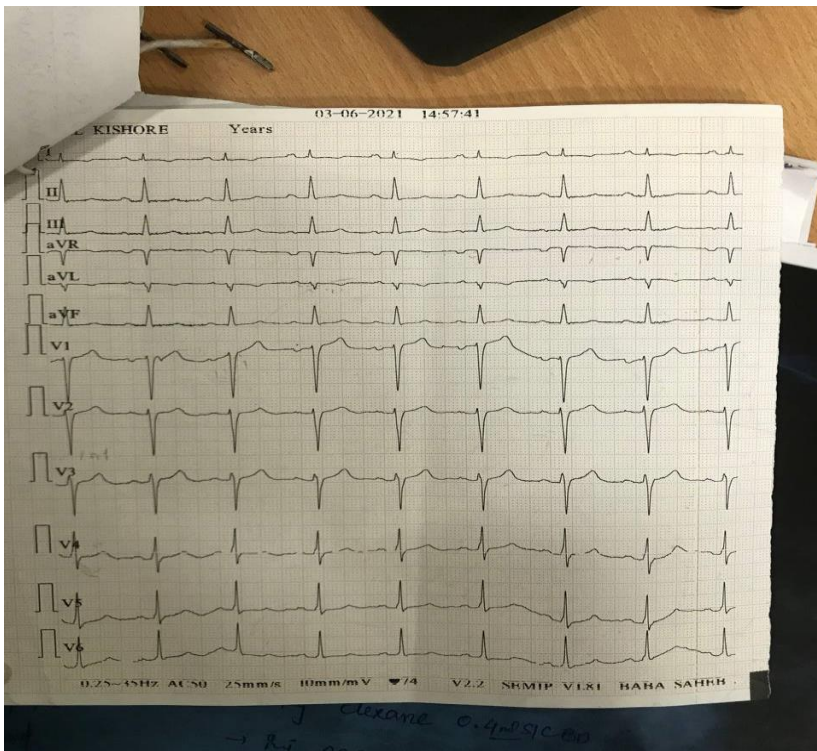


FIGURE 3: Ischemic changes in lead 1, avl

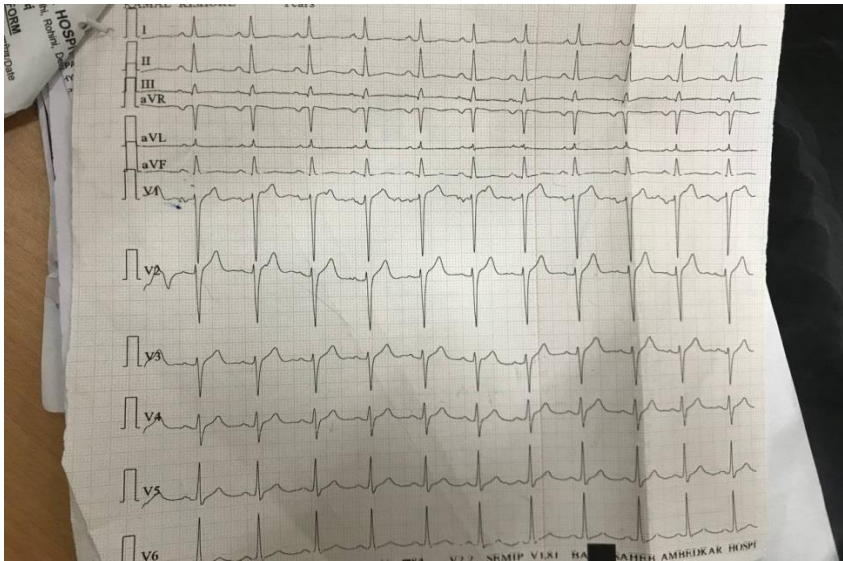


FIGURE 4:
resolution of
ischemic changes

V. PLEURAL EFFUSION

A 40 year old female patient presented with complaints of breathlessness and cough for a duration of 1 week. On examination she had a low oxygen saturation of 60% on room air and was in shock with very low blood pressure. Chest X Ray revealed bilateral infiltrates in the chest along with left sided pleural effusion. Along with the routine blood examinations, a pleural fluid analysis was done and a Rapid Antigen Test for COVID-19 was performed on pleural fluid which came out positive thus confirming the presence of the virus in the pleural fluid as opposed to the fact that pleural effusion is usually a manifestation of hypersensitivity reaction in COVID infection. Patient was managed on the lines of COVID-19 infection with I.V antibiotics, steroids, inotropes, oxygen support and low molecular weight heparin. However despite above measures patient remained hemodynamically unstable and passed away.

VI. DISCUSSION

COVID-19 is primarily known to involve the respiratory system, however gastrointestinal involvement has been found in upto 50% of the patients.⁶ Pancreatitis is a rare manifestation of COVID-19. Pancreatic injury in COVID-19 occurs due to the expression of angiotensin-converting enzyme 2 (ACE2) receptors in pancreatic cells. Glycosylated-spike (S) protein (structural protein encoded by the coronavirus genome) binds to ACE2 receptors located on the host cell membrane and results in host cell invasion.⁷ However direct cytopathic effects of COVID-19 or immune-mediated mechanisms have also been implicated in causing pancreatic injury resulting in acute pancreatitis.⁸ In the above case report our patient developed COVID-19 and later developed pancreatitis and right sided haemorrhagic pleural effusion which is a very rare manifestation of pancreatitis as most of the effusions in pancreatitis are reactive and left sided.⁹ Haemorrhagic pleural effusion is caused by various mechanisms that include transdiaphragmatic transfer of fluid by means of

lymphatics, perforation of pseudocyst via diaphragm and extension through mediastinum.⁹

COVID-19 is also known to affect the cardiovascular system leading to complications like, myocarditis, myocardial infarction, various arrhythmias, heart failure and thromboembolic events.¹¹ Various mechanisms have been postulated to cause myocardial injury in COVID-19 : T- cell mediated inflammation and cytokine storm leading to myocarditis, hypercoagulability leading to development of coronary microvascular thrombosis, diffuse endothelial injury in various organs including the heart, inflammation and stress resulting in coronary plaque rupture or mismatch of supply-demand leading to myocardial ischemia or infarction.¹² The SARS-CoV-2 can also lead to direct damage to heart via ACE2 receptors located in cardiac tissue.¹³

Isolated pleural effusion is a rare finding in patients with COVID-19 and is usually found along with lung parenchymal involvement.¹⁴ The mechanism of most of the exudative pleural effusion that occurs in infections involves pleural inflammation or as a result of a hypersensitivity reaction. However in our patient (case 4) it can be hypothesized that pleural effusion may have occurred due to viremia and direct invasion of the pleura by the virus itself (and not just as a manifestation of hypersensitivity reaction) as demonstrated by a positive rapid antigen test in the pleural fluid specimen. However further intensive studies would be needed to confirm this hypothesis.

REFERENCES

- [1] Xie J, Ding C, Li J, Wang Y, Guo H, Lu Z, Wang J, et al. Characteristics of patients with coronavirus disease (COVID-19) confirmed using an IgM-IgG antibody test. *J Med Virol.* 2020 Oct;92(10):2004-2010.
- [2] Behzad S, Aghaghazvini L, Radmard AR, Gholamrezanezhad A. Extrapulmonary manifestations of COVID-19: Radiologic and clinical overview. *Clin Imaging.* 2020 Oct;66:35-41.
- [3] Boxhoorn L, et al. Acute pancreatitis. *Lancet.* 2020;396:726-734.
- [4] Raghu MB, Balasubramanian S, Balasubramanyam G. Hemorrhagic pleural effusion: sole manifestation of pancreatitis. *Indian J Pediatr.* 1992;59:767-769.
- [5] Yousefi-Koma A, Naghashzadeh F, Figtree GA, Patel S, Karimi Galouhahi K. Multi-modality imaging of inflammation and ischemia for assessment of myocardial injury in Covid-19. *J Nucl Cardiol.* 2020 Jun 19:1-4.

- [6] COVID- 19: knowns, unknowns, and questions. Weston S, Frieman MB. *mSphere*. 2020;5:0–20.
- [7] Epidemiology, genetic recombination, and pathogenesis of coronaviruses. Su S, Wong G, Shi W, et al. *Trends Microbiol*. 2016;24:490–502.
- [8] Epidemiological, clinical and virological characteristics of 74 cases of coronavirus-infected disease 2019 (COVID-19) with gastrointestinal symptoms. Jin X, Lian JS, Hu JH, et al. *Gut*. 2020;69:1002–1009.
- [9] Raghu MB, Balasubraminian S, Balasubramanyam G. Hemorrhagic pleural effusion: sole manifestation of pancreatitis. *Indian J Pediatr*. 1992;59:767–769.
- [10] Ramsdell CM, Muslow I. Recurrent hemorrhagic pleural effusion associated with relapsing pancreatitis. *South Med J*. 1973;66:1016–1018.
- [11] Long B, Brady WJ, Koyfman A, Gottlieb M. Cardiovascular complications in COVID-19. *Am J Emerg Med*. 2020;38(7):1504-1507.
- [12] Bavishi C, Bonow RO, Trivedi V, Abbott JD, Messerli FH, Bhatt DL. Special Article - Acute myocardial injury in patients hospitalized with COVID-19 infection: A review. *Prog Cardiovasc Dis*. 2020;63(5):682-689.
- [13] Chen L., Li X., Chen M., Feng Y., Xiong C. The ACE2 expression in human heart indicates new potential mechanism of heart injury among patients infected with SARS-CoV-2. *Cardiovasc Res*. Mar 30 2020.
- [14] Hussein M, Haq IU, Hameed M, Thomas M, Elarabi A, Allingawi M, Al-Bozom I. Pleural effusion as an isolated finding in COVID-19 infection. *Respir Med Case Rep*. 2020 Oct 21;31:101269.

AUTHORS

First Author – Dr. Pratima Goyal

Second Author – Dr. Prashant Hiwale

Third Author – Dr. Narinder kumar Girdhar