

Assessment of Nipple Discharge in Symptomatic Patients attending a Main Breast Cancer Center in Baghdad using Ultrasound and Cytology

Khaleel Ibraheem Mohson* and Nada A. S. Alwan**

*MB.ChB, DMRD, CABMS (Rad) Lecturer of Radiology, National Cancer Research Center, Baghdad University

**MB.ChB, PhD (Pathology) Professor of Pathology, Director, National Cancer Research Center, Baghdad University

Abstract- Background: Nipple discharge is a symptomatic dilemma that causes women distress and worry. Ultrasonography is a vital complementary diagnostic device in the exploration of the etiology of nipple discharge.

Objectives: The aim of the study was to evaluate the role of the gray-scale ultrasound in the diagnosis of intraductal pathology in symptomatic patients with nipple discharge

Methods: A retrospective study included 100 patients who complained of nipple discharge attending the Main Training Center for Early Detection of Breast Tumors in the Oncology Teaching Hospital in Baghdad during the period from January 2015 to September 2015. Their age ranged from 17 to 69 years. Their ultrasound findings were reviewed and correlated with the corresponding cytopathology results.

Results: By reviewing nipple discharge cytology, inflammatory cell infiltration were observed in the majority of cases (66% of the examined symptomatic patients); 8% were cases of duct ectasia and 7% were diagnosed as mastitis. Benign neoplastic lesions were detected cytologically in 6% of cases; all of which presenting with bloody nipple discharge and given a diagnosis of intraductal papilloma. When correlating the ultrasound findings with smear cytology it was concluded that when ultrasound showed there was mild ductal dilation and clear ductal content, the corresponding cytology revealed inflammatory cell infiltration in 61% and 67% respectively. Inflammatory cell infiltrations were the main finding in patient who revealed moderate ductal dilation and turbid content on ultrasound which represented 70% and 82% respectively. In all patients with a cytological diagnosis of intraductal papilloma, ultrasound showed changes consistent with intraductal masses. No malignant cases were detected in the present study.

Conclusion: Ultrasonography is a required adjuvant tool, as a routine evaluation method of investigation in the assessment of causes behind nipple discharge. Its value was illustrated in localizing the ductal problems, assessing the wall thickness and content of the lesion and in defining intraductal abnormalities, especially papillomatous types.

Index Terms- breast ultrasound, nipple discharge, cytology smear, Baghdad

I. INTRODUCTION

Nipple discharge is a symptomatic problem that causes both discomfort and anxiety to many women specifically when

bloody in nature. Tremendous advances have been made in the management of breast problems, mainly through advances in diagnostic breast imaging [1]. The causes of nipple discharge are not well understood. However, nipple discharge is most commonly associated with endocrine alterations and/or medications. These often result in duct ectasia and/or fibrocystic changes in the breast [3]. Changes are often bilateral and may lead to discharge from one or several nipple ducts. The most common cause of clinically significant discharge is intraductal growth of the ductal epithelium, due to hyperplasia, micropapillary proliferation, solitary papillomas and/or ductal carcinoma (both in situ and invasive). Most of the intraductal changes that lead to nipple discharge are situated within 1-4cm of the nipple and the role of pathology in diagnosing these lesions has been investigated earlier [2].

Ultrasound (US) is an indispensable complementary diagnostic tool in the investigation of breast abnormalities [4]. At US, normal ducts are typically invisible; if seen, they appear as thin cylindrical anechoic or hypoechoic structures [8], a normal duct should decrease in diameter peripherally and should not have focal areas of dilatation along its course [9].

The current study was carried out to illustrate the value of US when used in concert with Cytopathology in diagnosing patients complaining of nipple discharge referred to a main center for early detection of breast cancer in Iraq.

Patients & methods

This is a retrospective study that comprised 100 patients complaining of nipple discharge referred to the Main Training Center for Early Detection of Breast Tumours in the Oncology Teaching Hospital in Baghdad during the period from January 2015 to September 2015. Their age ranged from 17 to 69 years.

All patients were subjected to ultrasonography performed by Siemens X300 using a 5-10MHz linear transducer. Patients were examined in supine position with breast and axilla fully exposed. The presence or absence of dilated ducts were assessed including their position, wall thickness and content (clear, turbid or mass filled). The presence or absence of any associated lesions was also evaluated.

The nipple was squeezed gently to obtain the discharge which was evaluated according to its color and content. The discharge was smeared directly onto glass slides which were immediately dipped in 99% ethanol for fixation. After 20 minutes, the fixed smears were stained with Papanicolaou Stain and examined cytological for any abnormal findings.

The ultrasonographic findings were correlated with the corresponding cytological results.

Results

One hundred patients presenting with nipple discharge were included in this study. Their ages ranged between 17 and 69 years (mean 43 years). The age of the patients and the color of discharge are shown in figures 1 and 2 respectively.

Table 1: Categorization of Ultrasound Findings in 100 Patients with Nipple Discharge.

Ultrasound findings		No.	%
Ductal changes	Dilatation	Normal	21 21%
		Mild *	62 62%
		Moderate	13 13%
		Severe	4 4%
	Distribution of dilated ducts	Retroareolar *	79 79%
		peripheral	0 0%
	Wall thickness	Normal *	77/79 97.5%
		Thick	2/79 2.5%
	Content	Clear *	53/79 67%
		Turbid	22/79 28%
Mass		4/79 5%	

Associated mass	Present	6	6%
	Absent	94	94%
Total		100	

*Most patients had mild, central ductal dilatation, normal duct wall thickness and clear content.

Associated lesions:

Associated masses were seen in six patients, two of them were fibroadenomas, and three were cysts while only one was proved to be carcinoma.

Findings of Nipple discharge smear cytology are displayed in Table 2:

Inflammatory cell infiltration were observed in the majority of cases (66%) of symptomatic patients; 8% were cases of duct ectasia and 7% were diagnosed as mastitis. Benign neoplastic lesions were detected in 6% of cases; all of which were given a diagnosis of intraductal papilloma (presenting with bloody nipple discharge). No malignant case was detected.

Nonspecific findings were observed in 24% in the form of foamy histiocytes infiltration and few benign-looking squamous metaplastic cells, while acellular smears were seen in 4%.

Table 2: Pathological Results of Nipple Discharge Cytology

Cytological finding of nipple smear		No.	%
Acellular		4	4%
Nonspecific		24	24%
Inflammatory		66	66% *
Neoplastic	Benign	6	6%
	Malignant	0	0%

*Inflammatory cells are the most common finding in Cytological smears

Table 3: Correlation between Ultrasound Findings versus Cytopathology Results.

	Ultrasound findings	Cytopathology Results				
		Acellular	Nonspecific	Inflammatory	Neoplastic	
					Benign	Malignant
Ductal changes	Mild dilation	4/62(6.5%)	16/62(26%)	38/62(61%)*	4/62(6.5%)	0
	Moderate dilation	0	2/13(15%)	9/13(70%)	2/13(15%)	0
	Severe dilation	0	0	4/4(100%)	0	0
	Normal	3/21(14.4%)	8/21(38%)	10/21(47.6%)	0	0
	Wall thickening	0	0	0	2/2(100%)	
Duct content	Clear	5/53(9%)	13/53(24.5%)	35/53(66.5%)	0	0
	Turbid	0	4/22(18%)	18/22(82%)	0	0
	Mass	0	0	0	4/4(100%)	

*Most patients with nipple discharge had mild ductal dilatation on ultrasound and inflammatory cells on smear cytology

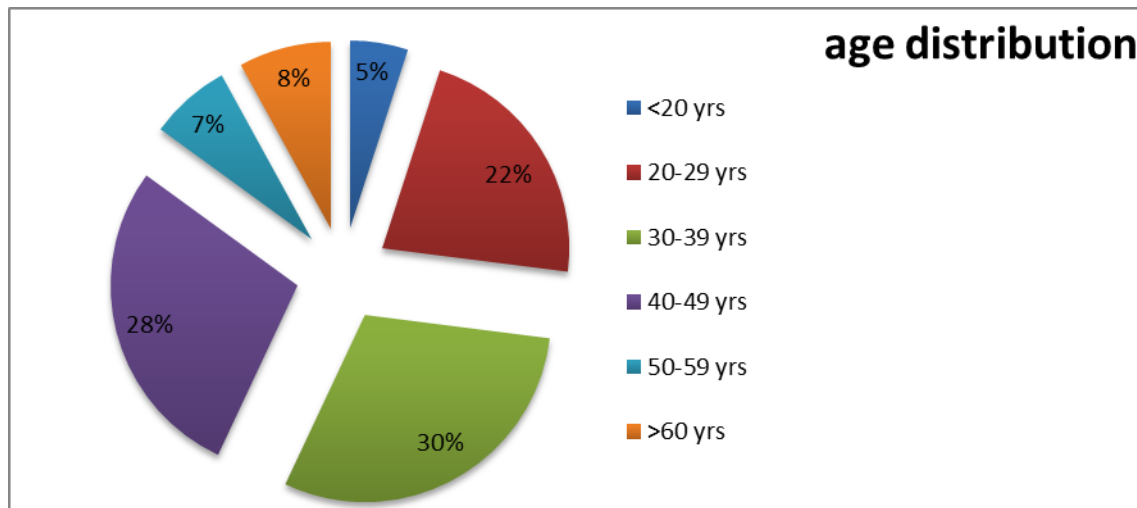
Table 3 reveals the Ultrasound findings versus the cytological results: When correlating the ultrasound findings with smear cytology it was concluded that when ultrasound showed there was mild ductal dilation and clear ductal content, the corresponding cytology revealed inflammatory cell infiltration n 61% and 67% respectively, while nonspecific and acellular findings were seen in 26% and 7% of mildly dilated ducts respectively. Ductal hyperplasia was noted in four patients with mildly dilated ducts which represent 6% of patients with mild duct dilation.

Inflammatory cell infiltrations were the main finding in patient who revealed moderate ductal dilation and turbid content on ultrasound which represent 70% and 82% respectively as the condition in patients with severe ductal dilation where inflammation was seen in all (100%)

When ultrasound report was normal in symptomatic females, cytology revealed inflammation in about 48%...

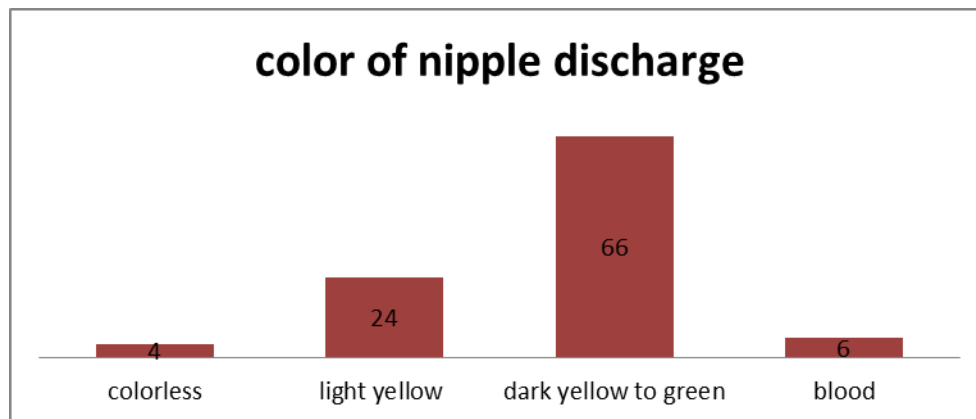
In all patients with intraductal mass on ultrasound, their smear results showed changes in favor of papilloma. As to the case where there was ductal thickening the cytology showed evidence of ductal hyperplasia.

Figure 1: Age Distribution of the Study Population



The majority of patients with nipple discharge were in their third, fourth and fifth decades (22%, 30% and 28% respectively).

Figure 2: Color of the Nipple discharge in the studied population



The Majority of nipple discharge were yellow to green in color which revealed inflammatory by cytology. All bloody nipple discharge showed benign cytological changes. No malignancy was detected.

II. DISCUSSION

Nipple discharge is the third most common complaint of patients seeking medical attention for breast disease, accounting for about 5% of all breast symptoms [15].

Spontaneous nipple discharge is a relatively common manifestation of breast disease. Bilateral nipple discharge involving multiple lactiferous ducts is usually non-pathological.

On the other hand, pathological nipple discharge is typically spontaneous, unilateral, uniductal and may be serous or bloody. The value of nipple discharge cytology has long been a subject of debate. It is usually practiced if patients are having active discharge at the time of assessment.

The commonest cause of bloody nipple discharge is intraductal papilloma or an underlying malignancy, usually ductal carcinoma in-situ. The likelihood of malignancy is greater in postmenopausal women or those presenting concurrently with a palpable mass [16, 17].

It has been reported that a benign nipple discharge cytological diagnosis does not exclude malignancy, and the false-positive/suspicious rate requires confirmation of a malignant nipple discharge prior to definitive patient management [18].

In our study we find that in majority the cause of nipple discharge is benign, ranging from inflammatory to nonspecific findings while the neoplastic is rare cause of nipple discharge especially when its bloody and this is in agree with literature [7]

Tremendous advances have been made in the management of breast problems, mainly through advances in diagnostic breast imaging. High-frequency transducers has significantly enhanced the contrast and spatial resolution of ultrasound in breast tissue. The quality of breast US is closely linked to the performance of the apparatus used for the examination and the talent of the examiner [5]. Linear, broad-bandwidth transducers with maximum frequencies of 10-13MHz are required to depict ductal abnormalities [6].

It has been demonstrated as well that Ultrasonography is not typically used unless the nipple discharge is accompanied by a palpable mass or a positive mammographic finding. It may be useful in presurgical localization if galactography reveals a dilated duct larger than a few millimeters in width. Nevertheless, it was shown that modern, high-resolution ultrasonographic techniques are becoming more sensitive for the visualization of intraductal changes. [18]

Other investigators displayed that Ultrasonography is indispensable as a complementary diagnostic tool in the investigation of breast abnormalities. However, ultrasonography is not commonly indicated for the evaluation of nipple discharge. Ultrasonography is an adjunctive tool for breast evaluation when more specific indications, including an abnormal mammographic finding or a palpable clinical finding, are present. Technological advances in high-resolution ultrasonography mean that in the future this modality may have a role in breast ductal evaluation [19, 20].

The current study revealed that inflammation was the leading cause of nipple discharge in the majority of patients in our study in whom ultrasound either showed mild, moderate or severe ductal dilation with either clear or turbid content. It is worthwhile mentioning that when moderate and severe ductal dilation was noted and when the ducts were echo filled that indicated inflammation in symptomatic patients. In conditions where masses were observed within the dilated ducts by US the cytopathology results revealed intraductal papilloma in all detected cases.

Sometimes the patient could be aware of nipple discharge early before gross ductal dilation seen by ultrasound as demonstrated in this study where the ultrasound was normal in

12 % of cases which showed inflammatory infiltration by cytology...

Ultrasound is safe, painless, doesn't entail radiation, noninvasive and is operator dependent [10]. The detection capability of ductal problems is high; providing the ability of the assessment of ductal content, wall thickness and presence or absence of masses. Within that respect, the results of the present study are comparable with those demonstrated by earlier reports (11,12). Our findings support other studies as well in illustrating that US can predict benignity of lesion [13] and in confirming the diagnosis of nipple discharge cytology [14].

Our findings on the other hand emphasize what has been concluded in earlier surveys, conducted in the same breast cancer center, that highlighted the importance of US and cytology in diagnosing breast lesions among symptomatic Iraqi patients (21, 22).

III. CONCLUSIONS

Ultrasound is an efficient, safe tool in diagnosing the cause behind nipple discharge, specifically when operated by experienced radiologists and high resolution device and when accompanied by thorough history, proper clinical examination and competent cytology results. It is thus recommended as an initial investigation in any patient presenting with nipple discharge.

REFERENCES

- [1] Azavedo E. Breast, Nipple Discharge Evaluation. E Medicine specialties. Radiology. Breast 10 June. 2005.
- [2] Baker KS, Davey DD, Stelling CB. Ductal abnormalities detected with galactography: Frequency of adequate excisional biopsy. AJR Am J Roentgenol. 1994, Apr 162 (4): 821-4.
- [3] Onstad M, et al. Benign breast disorders. Obstetrics and Gynecology Clinics of North America. 2013; 40:459.
- [4] Shalmali Pal. Ultrasound continues to make inroads in breast imaging, Aunt Minnie.com. Ultrasound digital community. 2/6/2007.
- [5] Hild F, Duda VF, Schulz KD. Ductal orientated sonography improves the diagnosis of pathological nipple discharge of the female breast compared with galactography. Eur J Cancer Prev 1998; 7(suppl 1):S57-S62.
- [6] Lam WWM, Chu WCW, Tang APY, Tse G, Ma TKF. Role of radiologic features in the management of papillary lesions of the breast. AJR Am J Roentgenol 2006; 186:1322-1327.
- [7] Non-cancerous breast conditions. American Cancer Society. <http://www.cancer.org/healthy/findcancerearly/womenshealth/non-cancerousbreastconditions/non-cancerous-breast-conditions-intro>.
- [8] Rumack CM, Wilson SR, Charboneau JW. Diagnostic ultrasound. St Louis, Mo: Mosby-Year Book, 1991
- [9] Kim KW, Cho KR, Seo BK, et al. Sonographic findings of mammary duct ectasia: can malignancy be differentiated from benign disease? J Breast Cancer 2010; 13(1):19-26
- [10] Cobbold, Richard S. C. (2007). Foundations of Biomedical Ultrasound. Oxford University Press. pp. 422-423. ISBN 978-0-19-516831-0
- [11] Hussain AN, Policarpio C, Vincent MT. Evaluating nipple discharge. Obstet Gynecol Surv 2006; 61:278-283
- [12] Rissanen T, Reinikainen H, Apaja-Sarkkinen M. Breast sonography in localizing the cause of nipple discharge: J Ultrasound Med 2007; 26:1031-1039
- [13] Adepoju LJ, Chun J, El-Tamer M, Ditkoff BA, Schnabel F, Joseph KA. The value of clinical characteristics and breast-imaging studies in predicting a histopathologic diagnosis of cancer or high-risk lesion in patients with spontaneous nipple discharge. Am J Surg 2005; 190:644-646

- [14] Kooistra BW, Wauters C, van de Ven S, Strobbe L. The diagnostic value of nipple discharge cytology in 618 consecutive patients. *Eur J Surg Oncol* 2009; 35:573-577
- [15] Hussain AN, Policarpio C, Vincent MT. Evaluating nipple discharge. *Obstet Gynecol Surv.* 2006; 61(4):278.
- [16] T. Richards, A. Hunt, S. Courtney, and H. Umeh, Nipple discharge: a sign of breast cancer? *Annals of the Royal College of Surgeons of England*, 2007; 89, no. 2, 124-126
- [17] M. H. Seltzer, Breast complaints, biopsies, and cancer correlated with age in 10,000 consecutive new surgical referrals, *The Breast Journal*, 2004; 10, no. 2, 111-117.
- [18] Patel BK, Falcon S, Drukteinis J. Management of nipple discharge and the associated imaging findings. *Am J Med.* 2015 Apr. 128 (4):353-60.
- [19] Bahl M, Baker JA, Greenup RA, Ghate SV. Diagnostic Value of Ultrasound in Female Patients With Nipple Discharge. *AJR Am J Roentgenol.* 2015 Jul. 205 (1):203-8.
- [20] Yoon H, Yoon JH, Kim EK, Moon HJ, Park BW, Kim MJ. Adding Ultrasound to the Evaluation of Patients with Pathologic Nipple Discharge to Diagnose Additional Breast Cancers: Preliminary Data. *Ultrasound Med Biol.* 2015 Aug. 41 (8):2099-107.
- [21] Alwan NAS: Iraqi Breast cancer: A review on patients demographic characteristics and clinicopathological presentations. *J.Fac, Med., Bagh. Univ.* 2010; 52 (1): 105-110
- [22] Alwan NAS: Clinicopathological evaluation of nuclear DNA ploidy and hormone receptor contents of breast tumours. PhD. Thesis, College of Medicine, Baghdad University, 1998.

AUTHORS

First Author – Khaleel Ibraheem Mohson, MB.ChB, DMRD, CABMS (Rad) Lecturer of Radiology, National Cancer Research Center, Baghdad University
Second Author – Nada A. S. Alwan, MB.ChB, PhD (Pathology) Professor of Pathology, Director, National Cancer Research Center, Baghdad University

الخلاصة

الخلفية: إفرازات الحلمة تعد مشكلة و تسبب للعديد من النساء الضيق والقلق، الفحص بالموجات فوق الصوتية (السونار) يعتبر حيويًا للتشخيص ومكمل في استكشاف الأسباب المؤدية إليها.

المقدمة: كان الهدف من هذه الدراسة هو تقييم دور الفحص بالموجات فوق الصوتية في تشخيص الاسباب المرضية في قنوات الحليب للمرضى اللواتي يعانون من أعراض إفرازات الحلمة.

المرضى والطرق: هذه هي دراسة رجعية لـ 100 مريضة شخّصت الاسباب المرضية للإفرازات الحلمية، و استعرضنا نتائج الموجات فوق الصوتية الخاصة بهم ربطها بنتائج المسحة الحلمية الخلوي.

النتائج: وأظهرت النتائج أن الغالبية العظمى من المرضى كان لديهم اتساع متوسط في الأفتنية (62 %) و محتوى صافي (67 %) . وكانت جميع القنوات المتوسعة خلف الحلمة في الموقع، وسمك الجدار اعتيادي في 97 % و كشف تحليل الخلايا التهاب في 66 % ، اما تمدد الأفتنية المتوسط شوهد في 13 % فيما كان اتساع الحاد الذي تشهده الموجات فوق الصوتية في 4 % من الحالات ، وكان محتوى الأفتنية عكر في 28 % ناتجة عن التهاب في 82 % و غير محددة في 28 % ، وكان الجدار سميك ينظر في اثنين من المرضى .

الاستنتاجات: الموجات فوق الصوتية هو فحص تكلمي ضروري لتقييم السبب الكامن وراء الإفرازات الحلمية.

مفتاح الكلمات: سونار الثدي، إفرازات الحلمية، المسح الخلوي للإفرازات الحلمية.