

Sublethal effects of phenolic compounds on biochemical, histological and ionoregulatory parameters in a tropical teleost fish *Oreochromis mossambicus* (Peters)

Remya Varadarajan, Hari Sankar H .S, Jisha Jose and Babu Philip

Department of Marine Biology, Microbiology & Biochemistry, Cochin University of Science & Technology, Fine Arts Avenue, Cochin – 16, Kerala, India

Abstract- Sub lethal toxicity of phenolic compounds in a tropical teleost fish *Oreochromis mossambicus* was investigated. Experimental animals were exposed to sub lethal (1/10th of 96 hr LC₅₀) concentration of phenol (3.12 mg l⁻¹) and m-cresol (2.2 mg l⁻¹) for a period of 21 days using a semi-static test bioassay system. Significant (P<0.05) lack of cortisol response was observed on exposure to both the phenolics. Furthermore total carbohydrate significantly (P<0.05) decreased in liver and muscle and blood glucose level was also significantly (P<0.05) decreased. The LDH (lactate dehydrogenase) showed significantly (P<0.05) elevated activity in the liver and kidney of fishes treated with phenol suggesting anaerobic glycolysis. Elevation in the activity (P<0.05) of ALT (alanine amino transferase) can be considered as a response to meet the excess energy demand. Increased serum ACP (acid phosphatase) activity suggests an increase in lysosomal mobilization. Also a significant (P<0.05) inhibition of branchial ATPases (Na⁺K⁺-ATPase, Mg²⁺-ATPase and Ca²⁺-ATPase) was observed. Moreover gill histopathological analysis on phenol exposure revealed severe lesions such as architectural loss, necrosis, desquamation of epithelial layer, hyperplasia and telangiectasis. Significant changes observed on m-cresol exposure were lamellar necrosis, lamellar shortening, telangiectasis and lamellar clubbing. Phenolic compounds even at very low concentrations (1/10th of 96 hr LC₅₀) for a short duration of 21 days induce metabolic stress, impair branchial functioning and are likely to induce tissue damage in *O. mossambicus*.

Index Terms- biomarker, branchial ATPases, m-cresol, fish, phenol

I. INTRODUCTION

Phenolic compounds are a group of wide spread xenobiotics. They are common constituents of aqueous effluents from the industrial processes such as resin production, oil refining and coking plants [1]. Aquatic biota uptake these pollutants directly from water, sediments, suspended and particulate matter. Phenols are listed among the potent chemical toxicants adversely affecting the aquatic habitats [2]. Among the different phenolic compounds, we were interested to study about phenols and cresols which are widely used as organic solvents. These compounds have also been identified in water- soluble fractions of crude oil since they are potential degradation products of aromatic hydrocarbon metabolism [3]. Also phenol is a toxic

metabolite of benzene, a ubiquitous industrial and environmental pollutant [4]. Phenol is among the first compound described as toxic by the Environmental Protection Agency - United States and due to its relevance as an ecotoxin it has been maintained in the priority list. Creosote is classified as a hazardous substance for occupational exposure [5]. Crude cresol (commercial grade) contains approximately 20% o-cresol, 40% m-cresol, and 30% p-cresol.

Fish can be used as bioindicators to evaluate the environmental contamination levels of hydrocarbons, because these pollutants tend to accumulate more in organisms than in the environment [6]. The aim of this study was to investigate the impact of sub-lethal concentrations (1/10th of LC₅₀/96 h) of phenol and m-cresol in a tropical teleost fish, *Oreochromis mossambicus*. For this biochemical, physiological and histological biomarkers were experimented by the end of the exposure period (21days).

II. RESEARCH ELABORATIONS

Animals and Experimental Exposure

Investigations were carried out in a fresh water fish *Oreochromis mossambicus* (15±3g) procured from the culture ponds of Kerala Agricultural University (Puduvypu), India. The water in the aquarium was renewed daily and was aerated mechanically. The average values of water quality parameters were as following: dissolved oxygen content of 7.8 ± 0.03 mg l⁻¹, hardness below detectable amounts, pH 7.0 ± 0.37, temperature 26 ± 30°C and salinity 0 ppt (parts per thousand) [7]. They were fed on a commercial diet *ad libitum* and were maintained in tanks for a month before the experiment in order to acclimate to the experimental system.

Sub-lethal toxicity studies

The acute LC₅₀ value of phenol and m-cresol was determined in the laboratory using semi-static method. The LC₅₀ levels and 95% confidence limits were calculated using Probit analysis [8]. The acclimated fishes (15±3 g) were divided into three groups (10 fishes each) in control and sub lethal concentrations of phenol and m-cresol. Triplicates were kept for both the treated groups and respective controls. Sub lethal concentration of phenol (3.12 mg l⁻¹) and m-cresol (2.2 mg l⁻¹), corresponding to 10% of the LC₅₀-96h of the respective compound was used. The system water was renewed every 24h (semi-static) with the same

concentrations of phenolic compounds so as to maintain the concentration. The exposure period was for 21 days.

Tissue and blood samples

At the end of 21 days tissues fishes were killed by pithing (by damaging the brain and severing the spinal cord between the head and trunk region using a sharp needle). Liver, gills, kidney and muscle tissues were dissected out and blood and other body fluids were removed using blotting paper. The tissues were washed in ice cold 0.33 M sucrose and again blotted dry and the desired amounts of tissues were weighed and used.

Blood was drawn from the common cardinal vein using 1 ml syringe and was then kept at room temperature for 30 minutes and then subjected to centrifugation at 3000 rpm for 3 minutes. The serum separated was stored at -20°C until assayed.

Biochemical studies

Blood was drawn from the common cardinal vein using 1 ml syringe and was then kept at room temperature for 30 minutes and then subjected to centrifugation at 3000 rpm for 3 minutes. The serum separated was stored at -20°C until assayed. The level of serum cortisol was estimated by electrochemiluminescence immunoassay (ECLIA) using Elecsys cortisol reagent kit, cat. No.11875116. The results were expressed as µg/dl. Total carbohydrate was estimated by the method of Carroll et al. [9]. The values were expressed as mg of glucose / g wet wt. of tissue. Glucose 6-phosphatase (EC 3.1.3.9) was assayed according to the method of King [10]. The enzyme activity was expressed as µg of inorganic phosphorus liberated / min / mg protein. Blood Glucose was estimated by the method of Sasaki et al. [11]. The values were expressed as mg glucose / dl. LDH (EC 1.1.1.27) was assayed according to the method of King [12] and the activity was expressed as µ moles of pyruvate liberated / h / mg protein. ALT (EC 2.6.1.2) was assayed by the method of Mohun and Cook [13] and expressed as µ moles of pyruvate liberated / h / mg protein. ACP (EC 3.1.3.2) was assayed by the method of King [14] and the activity was expressed as mg of phenol liberated / min / mg protein. Protein was estimated by the method of Lowry et.al. [15]. The values are expressed as mg of protein / g wet wt. of tissue. All the parameters were assayed using a Hitachi UV-visible spectrophotometer

Assay of Branchial ATPases

Estimation of Branchial ATPases was done using 10% gill homogenate prepared in 0.33 M sucrose, centrifuged at 3000×g for 15 minutes and the supernatant so obtained was centrifuged at 135,000×g for 30 minutes. The pellet so obtained corresponded to heavy microsomal fraction [16]. The pellet was then resuspended in cold 0.33 M sucrose and used as the enzyme source. Na⁺K⁺-ATPase activity was assayed according to the method of Bonting [17]. Ca²⁺-ATPase activity was assayed according to the method of Hjertson and Pan [18]. Mg²⁺-ATPase activity was assayed according to the method of Ohnishi et al. [19]. The phosphorus content was estimated by the method of Fiske and Subbaraow [20]. The enzyme activity was expressed as µmoles of Pi liberated/min/mg protein.

Histopathological studies

For histopathological studies fishes from each test groups as well as control group were sacrificed and gills were dissected out and fixed in Bouin's fixative for 48 h. They were then washed with running tap water overnight. The gills were decalcified in decalcifying agent (HNO₃ and 70% alcohol) for another 48 h. After dehydration in graded alcohol series, they were embedded in paraffin and sectioned at 5-6mm. The sections were stained in haematoxylin-eosin. Changes were examined under a Leica DM/LS type microscope with camera attachment and were photographed at both high as well as low power resolutions.

The statistical analysis was carried out using the software SPSS 13.0 package. One-way analysis of variance (ANOVA) was done and if significant differences were revealed by the ANOVA test, Tukey's test was used to further elucidate which treatments were significantly different from their respective control. All the data were presented as mean ± S.D and the differences were regarded as statistically significant at P<0.05.

III. RESULTS

Phenolic compounds induced changes in Biochemical parameters

One-way ANOVA followed by Tukey's test showed that there was significant (P<0.05) decrease in cortisol in both the phenolic compound treated groups compared to control as depicted in Fig.1.

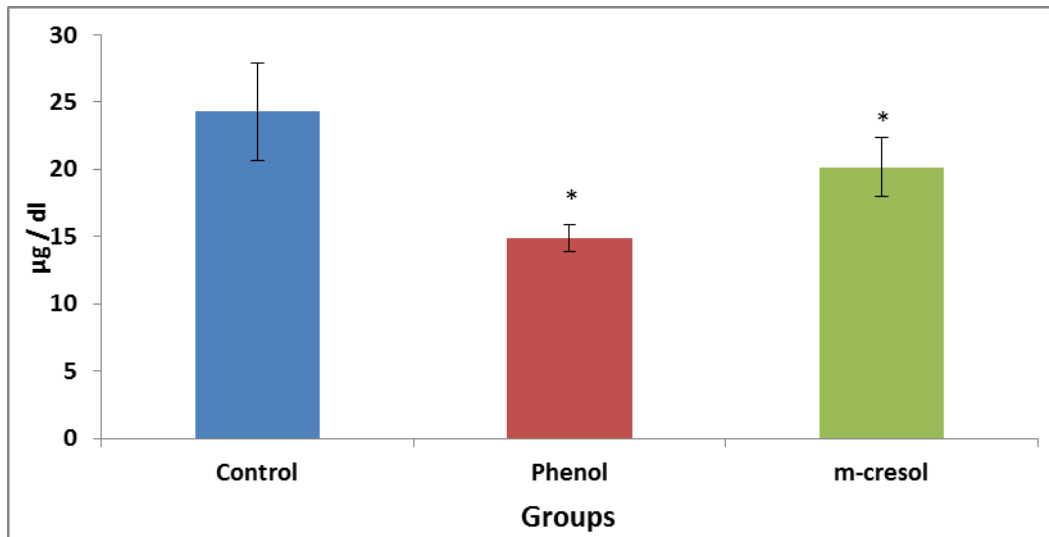


Figure 1. Effect of different phenolic compounds on cortisol in *O. mossambicus*. Values are expressed as $\mu\text{g/dl}$. Each value represents the mean \pm S.D of six separate experiments. * indicates significant ($P<0.05$) difference from control.

A statistically significant ($P<0.05$) decrease in total carbohydrate as illustrated in Fig. 2 was observed in liver and muscle of both the treated groups compared to control. Among the tissues, kidney showed significant ($P<0.05$) elevated

carbohydrate level in both the treated groups compared to control. No significant variation was observed in gills of both the treated groups compared to control.

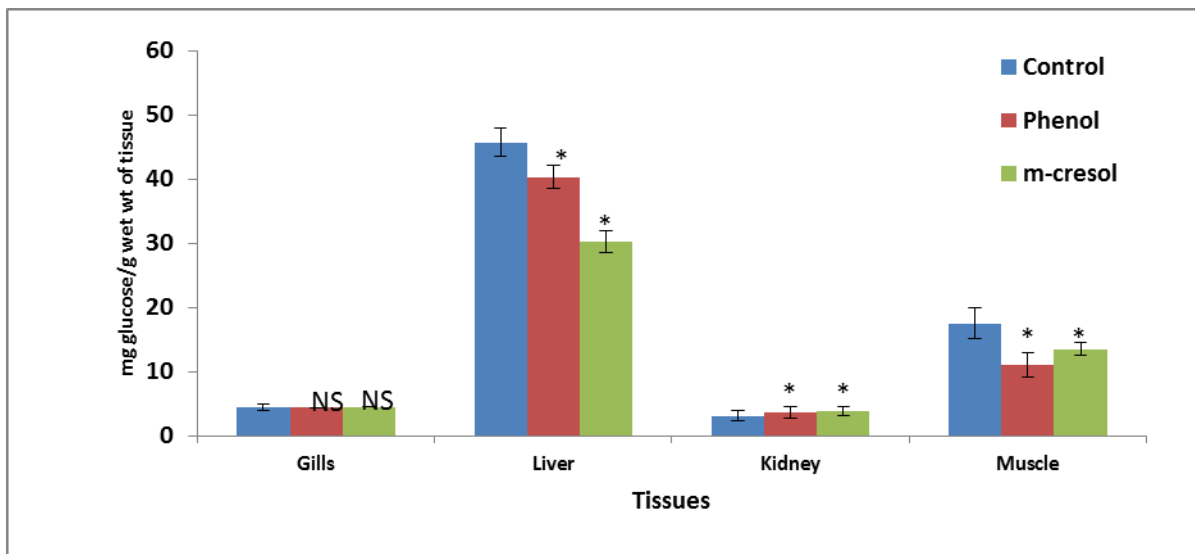


Figure 2: Effect of different phenolic compounds on total carbohydrate in *O. mossambicus*. Each bar diagram represents mean \pm S.D for $n=6$. On each set of bars, significant difference are marked by (*) for $P<0.05$ compared to the respective control (One-way ANOVA).

One-way ANOVA followed by Tukey's test showed that there was significant ($P<0.05$) decrease in glucose-6-phosphatase activity in both the treated groups compared to control (Fig.3).

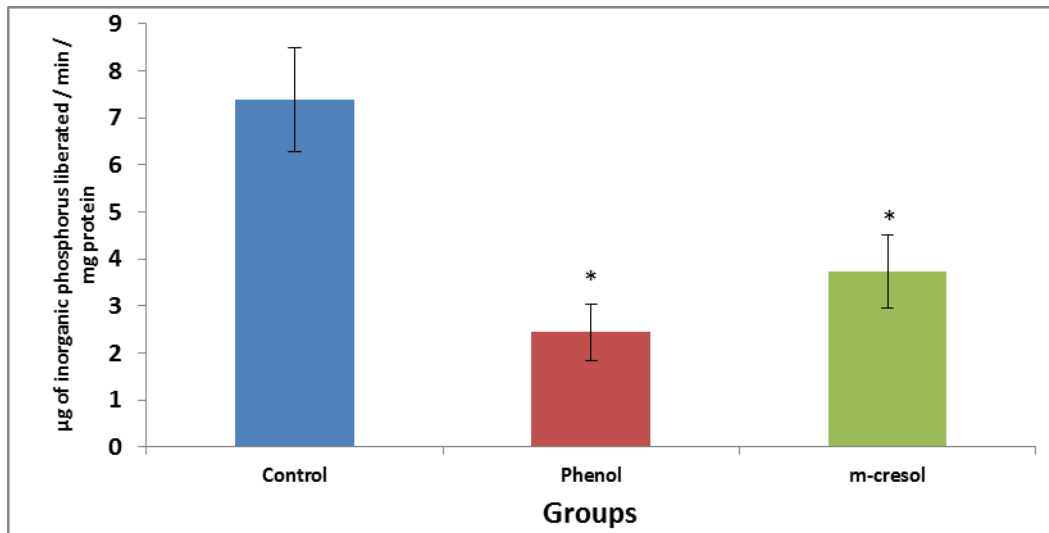


Figure 3. Effect of different phenolic compounds on glucose-6-phosphatase activity (mean \pm S.D) in *O. mossambicus*. Values are expressed as μg of inorganic phosphorus liberated/min/mg protein. Each value represents the mean \pm S.D of six separate experiments. * indicates significant ($P < 0.05$) difference from control.

One-way ANOVA followed by Tukey's test showed that there was significant ($P < 0.05$) decrease in blood glucose in both the treated groups compared to control (Fig.4).

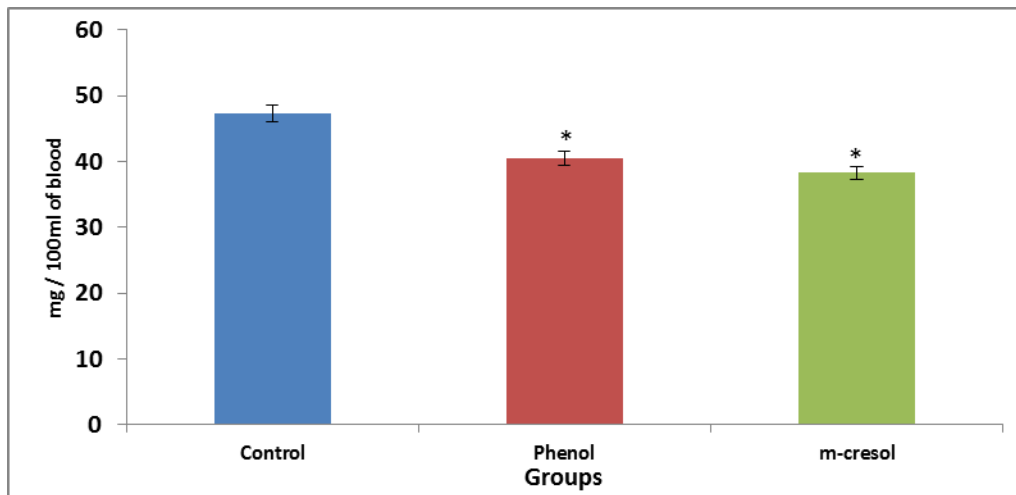


Figure 4. Effect of different phenolic compounds on blood glucose level (mean \pm S.D) in *O. mossambicus*. Values are expressed as mg/dl. Each value represents the mean \pm S.D of six separate experiments. * indicates significant ($P < 0.05$) difference from control.

As depicted in Fig.5 serum acid phosphates activity, showed a significant ($P < 0.05$) increase in both the treated groups compared to control.

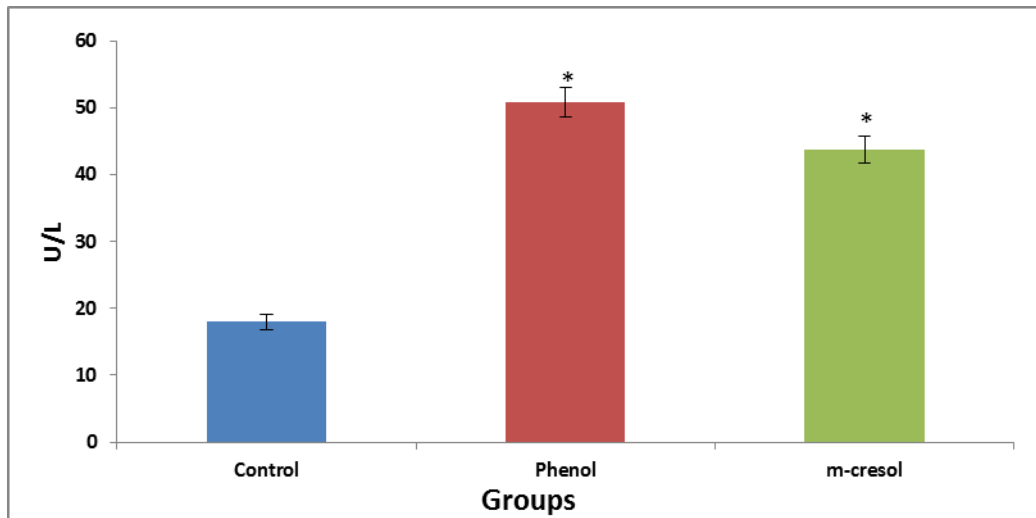


Figure 5. Effect of different phenolic compounds on serum ACP activity in *O. mossambicus*. Values are expressed as U/L. Each value represents the mean \pm S.D of six separate experiments. *indicates significant ($P < 0.05$) difference from control.

Significantly ($P < 0.05$) elevated LDH activity was observed in the phenol treated group as illustrated in Fig.6 in tissues such as liver, kidney and muscle compared to control. Among the tissues of m-cresol treated group, the gills and muscle showed

significantly ($P < 0.05$) elevated activity and the liver and kidney showed a significantly ($P < 0.05$) decreased activity compared to control.

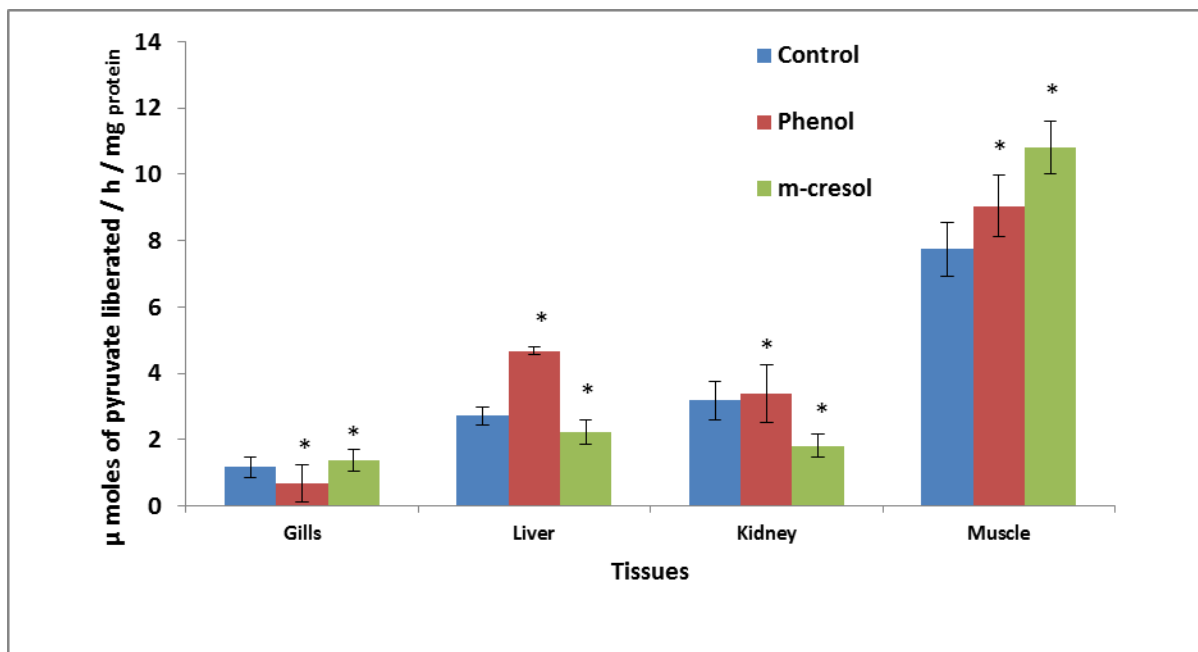


Figure 6: Effect of different phenolic compounds on lactate dehydrogenase activity in *O. mossambicus*. Each bar diagram represents mean \pm S.D for $n=6$. On each set of bars, significant difference are marked by (*) for $P < 0.05$ compared to the respective control (One-way ANOVA).

There was significant ($P < 0.05$) elevation in ALT activity (Fig. 7), in both the treated groups compared to control. Liver and kidney of phenol treated group showed significantly elevated

activity ($P < 0.05$) compared to m-cresol treated group. Gills and muscle of m-cresol treated group showed significantly elevated activity compared to phenol treated group.

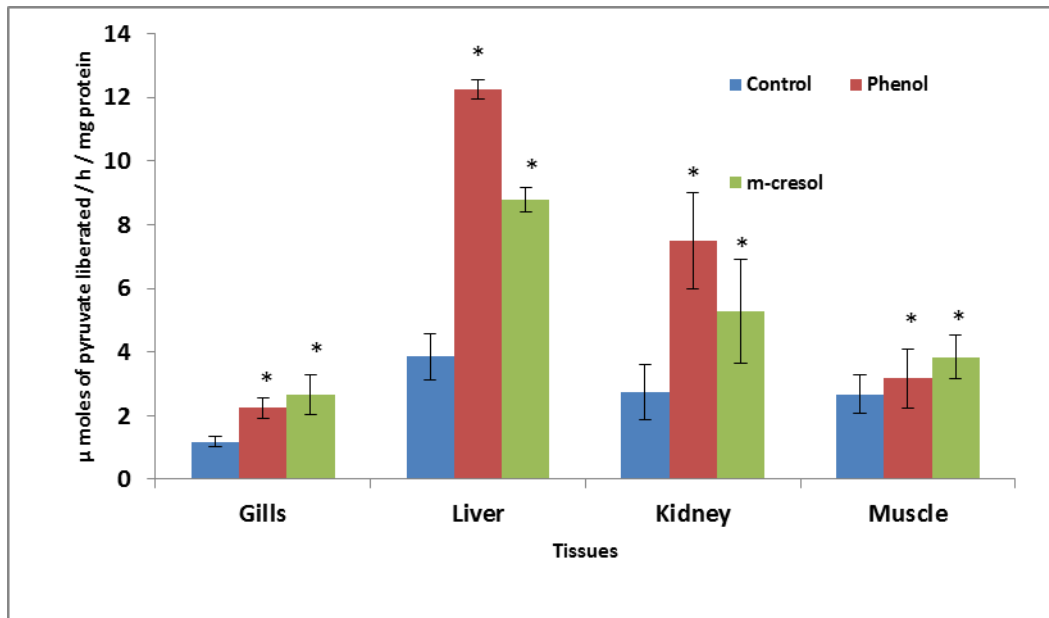


Figure 7: Effect of different phenolic compounds on ALT activity in *O. mossambicus*. Each bar diagram represents mean \pm S.D for n=6. On each set of bars, significant difference are marked by (*) for P<0.05 compared to the respective control (One-way ANOVA).

Statistically significant (P<0.05) decreased protein level as shown in Fig. 8, was observed in liver and muscle of both the treated groups compared to control. Gills and kidney of both the

treated groups showed a significantly (P<0.05) elevated protein level compared to control.

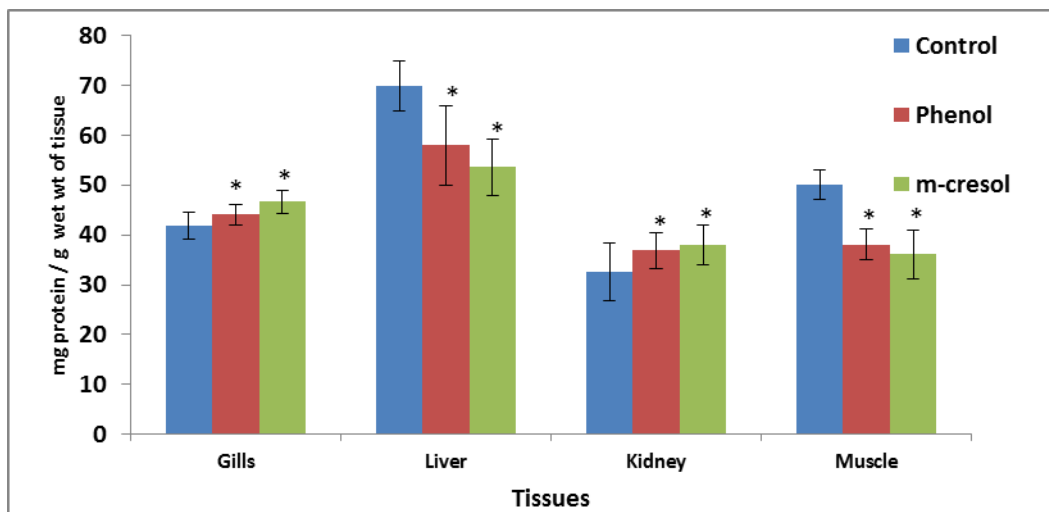


Figure 8: Effect of different phenolic compounds on total protein level (mean \pm S.D) in *O. mossambicus*. Each bar diagram represents mean \pm S.D for n=6. On each set of bars, significant difference are marked by (*) for P<0.05 compared to the respective control (One-way ANOVA).

Effect of Phenolic compounds on Branchial ATPases

Comparison between different treatments as illustrated in Table 1. revealed that there was significant (P<0.05) decrease in Na⁺K⁺-ATPase, Ca²⁺-ATPase and Mg²⁺-ATPase activities in both phenol and m-cresol treated groups compared to control. Statistical analysis also showed that phenol treated group showed the least activity compared to m-cresol treated group.

Table 1. Effect of different phenolic compounds on branchial ATPases activity in *O. mossambicus*. Values in the same row with different lower case letters vary significantly (P<0.05) between treatment groups (One-way ANOVA). Each value represents the mean \pm S.D of six separate experiments. Values are expressed as μ moles of inorganic phosphorus liberated/min/mg protein.

Branchial ATPases	Control	Phenol	m-cresol
Na ⁺ K ⁺ -ATPase	12.38 ± 0.27 ^c	4.53 ± 0.24 ^a	8.89 ± 0.34 ^b
Ca ²⁺ -ATPase	14.49 ± 0.54 ^c	9.66 ± 0.50 ^a	12.51 ± 0.78 ^b
Mg ²⁺ -ATPase	11.35 ± 1.37 ^c	7.42 ± 0.13 ^a	9.85 ± 1.86 ^b

Histopathological changes in gill tissue on exposure to phenolic compounds

Gills of fish in control group showed no histopathological abnormalities. The structural details of the gills of control group *O. mossambicus* are shown in Fig. 9 (a). As shown in Figure 9 (a), gills are made up of double rows of filaments from which arise perpendicularly the lamellae. The lamellae are lined by

squamous epithelium composed of pavement and non differentiated cells. Below that epithelium are lamellar blood sinuses separated by pillar cells. Between the lamellae, the filament is lined by a thick stratified epithelium constituted by several cellular types, such as chloride, mucus and pavement cells. In the phenol treated group, the histopathological changes in gills observed were architectural loss, necrosis, desquamation of epithelial layer, hyperplasia and telangiectesis, Fig. 9 (b, c, and d). On exposure to m-cresol, the most significant histopathological changes observed in gills were lamellar necrosis, lamellar shortening, telangiectesis and lamellar clubbing as illustrated in Fig. 9 (e and f).

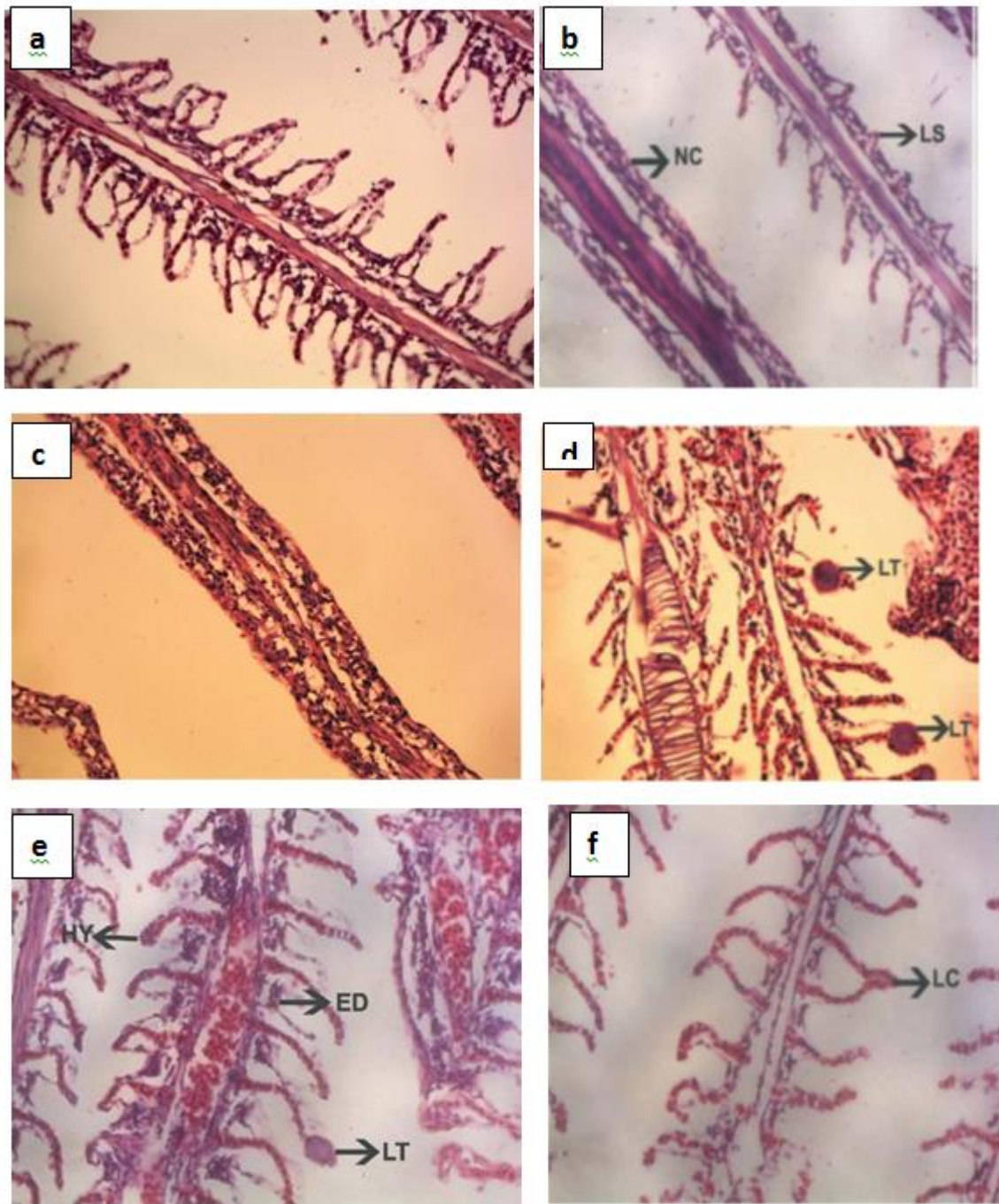


Figure 9. Histopathological changes observed in the gill tissue of *O. mossambicus* on exposure to different phenolic compounds a) control gill architecture with primary lamellae and secondary lamellae (40X) b) phenol treated showing complete necrosis of secondary lamellae (40X) c) phenol treated group showing hyperplasia (HY), epithelial desquamation (ED) and lamellar telangiectasis (LT) (40X) d) m-cresol treated group showing lamellar necrosis (LN) and lamellar shortening (LS) (40X) e) lamellar telangiectasis (LT) (40X) f) m-cresol treated group showing lamellar clubbing (LC) (40X).

IV. DISCUSSION

The overall results observed points to the adverse effects of very low concentrations (1/10th of LC_{50} value) of the tested phenolic compounds that altered normal metabolism of

O. mossambicus. The lack of cortisol response suggests that, similar to other xenobiotics phenol and m-cresol can act as endocrine disruptors and as such impair steroidogenesis. There are some experimental observations with possible explanations for this, first; it might be possible that one of the primary steps in the steroid hormone synthesis pathway was compromised.

Cholesterol is the substrate for steroid synthesis [21], particularly the non-esterified cholesterol. It has been demonstrated in carp (*Cyprinus carpio*) that chronic exposure to water-borne phenol (8 mg l⁻¹) caused significant accumulation of non-esterified cholesterol in both tissues and serum by days 15 and 30 of exposure, respectively [22]. This accumulation was due to the inability of the steroidogenic tissues to synthesize steroids. It has also been shown that xenobiotics can inhibit the transport of cholesterol to the mitochondria [23-24]. There are several studies which provided evidence that the capacity to raise plasma cortisol is impaired in fish exposed to organic pollutants [25] and metals [26, 27, 28] which is in agreement with our decreased cortisol response. Studies [29] on the impact of three pharmaceuticals (acetaminophen, ibuprofen and salicylic acid) in rainbow trout supported the hypothesis that these pharmaceuticals disrupt steroidogenesis in fish interrenal tissue. Similar results were also reported [30] in the neotropical fish *Prochilodus lineatus* exposed to water-soluble fraction of diesel oil for 15 days. Therefore many pollutants halt cortisol secretion and hence even if the fish is under stress this will probably not be reflected as an increased cortisol response. Fish exhibiting an impaired cortisol stress response may be at a disadvantage in coping with environmental stressors thereby attenuating the chances of coping with subsequent natural or anthropogenic stressors. Perhaps a future research targeted at endocrine study at the hypothalamo pituitary interrenal axis is also under consideration. We observed a decrease in total carbohydrate content in liver and muscle of both the treated groups. There are studies reported which show that chemical stress causes rapid depletion of stored carbohydrates primarily in liver and other tissues [31]. Hence detoxification mechanisms become active and the hepatic synthesis of detoxifying enzymes requires high energy levels that might be derived from carbohydrate metabolism, for driving the various enzyme-mediated reactions. UDP-glucuronic acid is an important carbohydrate derivative. Phenolics are often excreted as glucuronyl derivatives by conjugating with UDP-glucuronic acid. UDPglucuronyltransferases (UGTs) are one of the phase II enzymes that catalyse this conjugation. UGTs are induced by a variety of natural and synthetic compounds and play a key role in catalyzing the conjugation and potential excretion of different xenobiotics in fish [32]. Inhibition of glucose-6-phosphatase activity in the liver may be a reflection of damage to the microsomal membrane as the enzyme is localized exclusively in the membranes of the endoplasmic reticulum. Also a decreased blood glucose level was observed in both the treated groups. Varying levels of blood glucose were also noticed [33] as indicative of abnormal carbohydrate metabolism and possibly the result of impaired hormonal control. Experimental groups of monosex tilapia exposed to deltamethrin also exhibited decreased blood glucose [34] which was due to either decrease in the synthesis of blood glucose regulating hormones or enhanced energy demand that stimulates utilization and exhaustion of glucose. These results points to the fact that blood glucose homeostasis was not maintained on exposure to phenolics.

LDH, an anaerobic enzyme showed elevated activity in liver and kidney of fishes treated with phenol. The increase in LDH activity also suggests a significant increase in the conversion of pyruvate to lactic acid, thereby leading to the accumulation of

lactic acid. Similar increase in LDH activity in juvenile Australian Bass and *Macquaria novemaculeata* in response to two different crude oil spills have also been reported [35]. Decreased LDH activity in liver and kidney of m-cresol treated group and in gills of fishes treated with phenol may be due to increased tissue damage. Similar results were obtained when *O. mossambicus* were exposed to sub-lethal concentrations of organophosphorus insecticide [36]. Stimulation of LDH in muscle of *O. mossambicus* on exposure to phenolic compounds suggests that the final product of glycolysis - pyruvate was preferentially used to produce lactate. Lactate formed is an important gluconeogenic substrate which can be used to cope with the high and rapid demand of energy due to stress. LDH is an important glycolytic enzyme in biological systems and is inducible by oxygen stress. The activity of lactate dehydrogenase sustains the continued process of glycolysis under anaerobic conditions [37]. The level of LDH was found to be increased in the gills and decreased in the liver, kidney and muscles in the monocrotophos exposed fish [38].

ALT an enzyme frequently used in the diagnosis of damage caused by pollutants in various tissues [39, 40] was highly elevated in all the tissues of fishes treated with phenol and m-cresol. Thus elevation in activity of ALT in different tissues of *O. mossambicus* can be considered as a response to the stress induced by phenolic compounds to generate keto acids for contributing to gluconeogenesis and/or energy production necessary to meet the excess energy demand. An elevation in ACP activity suggests an increase in lysosomal mobilization and cell necrosis due to the toxicity of phenolics. This increase also suggests the supply of phosphate group for energy metabolism. This shows an adverse impact on metabolism, which may lead to negative impact on growth, health and reproduction. Degeneration and necrosis induced in hepatic parenchymatous cells by these toxicants may have caused release of acid phosphatase in the serum. Alterations in ACP activities in tissues and serum have been reported in pesticide treated fish [41].

The reduction in protein content in liver and muscle of both the treated groups indicates that under stress conditions the tissue protein may undergo proteolysis, which may have resulted in the production of free amino acids which can be used in the tricarboxylic acid cycle for energy production. The tissue protein is metabolized to produce glucose by the process of gluconeogenesis and it is utilized for energy production under stress conditions [42]. The decrease in protein content in gills and kidneys may be attributed to stress induced by phenolic compounds for the utilization of amino acids in various catabolic reactions. Yadav et al. [43] has reported that the animals exposed to chemicals obtain extra energy requirement from the tissue protein. The depletion of protein content may thus be due to the rapid utilization of tissue protein as the food utilization decreases when the animals are under stress conditions.

Na⁺K⁺-ATPase, an important membrane bound enzyme in gills showed a decreased activity in both the phenolic compound dosed groups. Thus, any toxicant that interferes with ionic homeostasis may be reflected as altered Na⁺K⁺-ATPase activity which was found to be decreased in the present investigation. This could be due to the effect of phenolic compounds on cell membrane because of their strong affinity for interaction with membrane lipids causing inhibition of membrane-bound

ATPases activity by affecting enzyme complex [44]. Xenobiotics can also alter Na^+K^+ -ATPase activity by disrupting energy-producing metabolic pathways or interacting directly with the enzyme [45.] As the primary link between environmental change and physiological response, the neuroendocrine system is a critical part of osmoregulatory adaptations [46]. Cortisol can increase the cellular differentiation of chloride cells and stimulate branchial Na^+K^+ -ATPase activity [47]. But on exposure to phenolics we observed a decreased cortisol response which may have resulted in decreased ATPase activity. Decreased Ca^{2+} -ATPase and Mg^{2+} -ATPase activities were also observed in both the treated groups. A reduction in the activity of Ca^{2+} -ATPases indicated the interaction of phenolic compounds with the microsomal and basolateral Ca^{2+} transporting ATPases [48]. Parvez et al. [49] observed decreased gill ATPase activities in the freshwater fish *Channa punctata* (Bloch) exposed to a diluted paper mill effluent. Chromium compounds were reported to inhibit ATPases, bringing about a failure of osmoregulatory mechanisms [50]. However, it is not clear how the organism compensate for ionic regulation in the face of exposures to environmental pollutants.

Pathological abnormalities in gills such as lamellar necrosis and complete desquamation of the gill epithelium provide evidence for the decreased branchial ATPase activity. Another important histopathological change observed was hyperplasia. Hyperplasia observed maybe the fish's response (1) to ward off or block something that irritates its tissues, whether externally or internally, or (2) to quickly heal an injured or irritated site. Hyperplasia, however, may play a role in the early stages of neoplasia. Increased mucus production and fusion of lamellae were obvious on exposure to both the phenolic compounds. Mucus cells contain mucins, polyanions composed of glycoproteins that can be effective in trapping toxicants and aid in the prevention of toxicant entry into the gill epithelium [51]. Extensive epithelial desquamation was also observed on phenol exposure. After acute exposure to hexavalent chromium, *Channa punctatus* also exhibited marked degenerative changes in the histology of gills, kidney and liver tissues [52]. Lamellar telangiectasis (localised dilation of blood vessel) observed results from the collapse of the pillar cell system and breakdown of vascular integrity with a release of large quantities of blood that push the lamellar epithelium outward [53]. Shortening and clubbing of ends of the secondary gill lamellae and clubbing of adjacent lamellae were well marked in the m-cresol treated group. Complete lamellar fusion may have reduced the total surface area for gas exchange. As fish gills are critical organs for their respiratory and osmoregulatory functions, the injuries in gill tissues observed as a result of exposure to phenolic compounds may have reduced the oxygen consumption and resulted in the disruption of the osmoregulatory functions of the fish. Any change in gill morphology may result in perturbed osmotic and ionic status which was observed as decreased branchial ATPases activity. The defense responses will take place at the expense of the respiratory efficiency of the gills and eventually results in the respiratory impairment.

To conclude, intoxication due to phenolic compounds lead to significant changes in the metabolic profile of *O. mossambicus* and the cause for these alterations appear to be the result of high energy demands. The foregoing results also showed that the

branchial ATPases are very sensitive to chemical interaction and can be used as reliable biomarker for toxicity studies in phenolic compounds. The present histological investigations demonstrate a direct correlation between metabolic changes and histopathological disorders observed. From the results obtained, it is possible to consider that phenolic compounds can cause potential risk to the health of aquatic organisms even at very low concentrations (1/10th of LC_{50} value) for a short duration of 21 days, which can in turn affect the growth and vital functions.

ACKNOWLEDGMENT

The authors are indebted to Cochin University of Science & Technology and University Grants Commission, New Delhi for the financial support. Our sincere thanks to Dr. K.C. George for his invaluable help and expertise in histopathological studies. We also thank Dr. Jose who had unflinchingly made arrangements for providing the experimental animal.

REFERENCES

- [1] M. Kibret, W. Somitsch, K.H. Robra, "Characterization of a phenol degrading mixed population by enzyme assay", Water. Res. 2000, Vol. 34, 1127– 1134.
- [2] M. D. Ibrahim, "Experimental exposure of African catfish *Clarias Gariepinus* (Burchell, 1822) to phenol: Clinical evaluation, tissue alterations and residue assessment", Journal of Advanced Research, 2012, Vol. 3, 177– 183
- [3] T. Saeed, M. Al-Mutairi, "Chemical composition of the water-soluble fraction of leaded gasolines in sea water", Environ. Int. 1999, Vol. 25, 117– 29.
- [4] M.A Medinsky, P.M. Schlosser, J.A Bond, "Critical Issues in Benzene Toxicity and Metabolism: the Effect of Interactions with Other Organic Chemicals on Risk Assessment", Environ. Health Perspect. 1994, Vol. 102, 119-124.
- [5] Chemwatch, Creosote oil acenaphthene fraction. Chemwatch, MSDS Data Sheet. 2006, pp. 1–19.
- [6] C. Anyakora, A. Ogbecbe, P. Palmer, H. Coker, "Determination of polynuclear aromatic hydrocarbons in marine samples of Siokolo Fishing Settlement", J. Chromatogr. A. Vol. 1073, 2005, 323–30.
- [7] APHA, Standard Methods for the Examination of Water and Wastewater, Washington, DC, 2005, 21st Edn.
- [8] D.J. Finney, Probit Analysis, 3rd edn. Cambridge University Press, New York, 1971. pp-337.
- [9] N.V. Carrol, R.W. Longley, J.H. Row, "Glycogen determination in liver and muscle by use of anthrone reagent", J. Biol. Chem. Vol. 22, 1956, 583- 593.
- [10] J.King, "The acid and alkaline phosphatases", In: D. Van (ed). Practical Clinical Enzymology. Nostrand Co., London. 1965 b. pp. 191-208.
- [11] T. Sasaki, A. Sanne, "Effect of acetic acid concentration of the colour reaction in the O-toluidine boric acid for blood glucose determination", Rinsho Kagaku. 1972, Vol.1, 346-343.
- [12] J. King, The dehydrogenases or oxidoreductases. Lactate dehydrogenase In: Practical Clinical Enzymology. London: Van Nostrand, D. Company Ltd. 1965 a. pp.83-93.
- [13] A.F. Mohun, I.J.Y. Cook, "Simple methods for measuring serum levels of glutamic-oxalo acetic and glutamic- pyruvic transaminase in routine laboratories", 1957, J.Clin. Pathol. Vol. 10, 394-399.
- [14] J.King, "The acid and alkaline phosphatases", In: D. Van (ed). Practical Clinical Enzymology. Nostrand Co., London. 1965 b. pp. 191-208.
- [15] O.H. Lowry, N.J. Rosenbrough, A.L. Farr, R.J. Randall, "Protein measurement with Folin Phenol reagent" J. Biol. Chem. 1951, Vol. 193, 265-275.
- [16] P.W. Davis, "Inhibition of Na^+K^+ activated ATPase activity by ethacrynic acid. Biochem. Pharmacol" 1970, Vol. 19, 1983-1989.

- [17] S. L. Bonting, "Sodium-potassium activated adenosinetriphosphatase and cation transport", In *Membranes and Ion Transport*, V.1, ed. Bittar, E. E., Wiley-Interscience, London. 1970, 257-263.
- [18] S. Hjertson, H. Pan, "Purification and characterization of two forms of a low affinity Ca²⁺-ATPase from erythrocyte membranes", *Biochim. Biophys. Acta.* 1983, Vol. 728, 281-288.
- [19] T. Ohnishi, T. Suzuki, K. Ozawa, "A comparative study of plasma membrane magnesium ion ATPase activities in normal, regenerating and malignant cells", *Biochim. Biophys. Acta.* 1982, Vol. 684, 67-74.
- [20] C.H. Fiske, Y. Subbarow, "The colorimetric determination of phosphorus", *J. Biol. Chem.* 1925, Vol. 66, 375-400.
- [21] T.P. Mommsen, M.M. Vijayan, T.W. Moon, "Cortisol in teleosts: dynamics, mechanisms of action and metabolic regulation", *Rev. Fish Biol. Fish.* 1999, Vol. 9, 211-268.
- [22] D. Mukherjee, S. Bhattacharya, V. Kumar, J. Moitra, "Biological significance of [¹⁴C] phenol accumulation in different organs of a murrel, *Channa punctatus*, and the common carp, *Cyprinus carpio*", *Biomed. Environ. Sci.* 1990, Vol. 3, 337-342.
- [23] A. Hontela, "Endocrine and physiological responses of fish to xenobiotics: role of glucocorticoid hormones", *Crit. Rev. Toxicol.* 1997, Vol. 1, 159-206.
- [24] L.P. Walsh, C. McCormick, C. Martin, D.M. Stocco, "Roundup inhibits steroidogenesis by disrupting steroidogenic acute regulatory (STAR) protein expression", *Environ. Health. Perspect.* 2000, Vol. 108, 769-776.
- [25] N. Aluru, E.H. Jorgensen, A. Maule, M.M. Vijayan, "PCB disruption of the hypothalamo-pituitary-interrenal axis involves brain glucocorticoid receptor down regulation in anadromous Arctic char", *Am. J. Physiol.* Vol. 287, 2004, 787-793.
- [26] J.C. Brodeur, G. Sherwood, J.B. Rasmussen, A. Hontela, "Impaired cortisol secretion in yellow perch (*Perca flavescens*) from lakes contaminated by heavy metals: in vivo and in vitro assessment", *Can. J. Fish. Aquat. Sci.* Vol. 54, 1997, 2752-2758.
- [27] D.O. Norris, S.B. Felt, J.D. Woodling, R.M. Dores, "Immunocytochemical and histological differences in the interrenal axis of feral brown trout, *Salmo trutta*, in metal-contaminated water", *Gen. Comp. Endocrinol.* 1997, Vol. 108, 343-351.
- [28] H. Levesque, J. Dorval, G. Van Der Kraak, P.G.C. Campbell, A. Hontela, "Hormonal, morphological and physiological responses of yellow perch (*Perca flavescens*) to chronic environmental metal exposure", *J. Toxicol. Environ. Health.* 2003, Vol. 66, 657-676.
- [29] A. Gravel, M.M. Vijayan, "Salicylate disrupts interrenal steroidogenesis and brain glucocorticoid receptor expression in rainbow trout", *Toxicol. Sci.* 2006, Vol. 93, 41-49.
- [30] J.D. Simonato, C.L. Guedes, C.B. Martinez, "Biochemical, physiological, and histological changes in the neotropical fish *Prochilodus lineatus* exposed to diesel oil", *Ecotoxicol. Environ. Saf.* 2008, Vol. 69, 112-120
- [31] B. Jyothi, G. Narayan, "Pesticide induced alterations of non-protein nitrogenous constituents in the serum of a freshwater catfish, *Clarias batrachus* (Linn.)", *Indian J. Exp. Biol.* 2000, Vol. 38, 1058-1061.
- [32] D.J. Clarke, S.G. George, B. Burchell, "Multiplicity of UDP-glucuronosyltransferases in fish. Purification of UDP-glucuronosyltransferase from the liver of a marine teleost. *Pleuronectes platessa*", *Biochemical Journal.* 1992a, Vol. 284, 417-423.
- [33] Shah 2002
- [34] Y.S. El-Sayed, T.T. Saad, S.M. El-Bahr, "Acute intoxication of deltamethrin in monosex Nile tilapia, *Oreochromis niloticus* with special reference to the clinical, biochemical and haematological effects", *Environ. Toxicol. Pharmacol.* 2007, Vol. 24, 212-21.
- [35] A. Cohen, D. Nugegoda, M.M. Gagnon, "Metabolic Responses of fish following exposure to two different oil spills Remediation Techniques", *Ecotoxicol. Environ. Saf.* 2001, Vol. 48, 306-310.
- [36] J.V. Rao, "Biochemical alterations in euryhaline fish, *Oreochromis mossambicus* exposed to sub-lethal concentrations of an organophosphorus insecticide, monocrotophos", *Chemosphere.* 2006, Vol. 65, 1814-1820.
- [37] T.C. Diamantino, E. Almeida, A.M.V.M. Soares, L. Guilhermino, "Lactate dehydrogenase activity - an effective parameter in aquatic toxicity tests", *Chemosphere.* 2001, Vol. 45, 553-560.
- [38] S. Agrahari, K. Gopal, "Fluctuations of certain biochemical constituents and marker enzymes as a consequence of monocrotophos toxicity in the edible freshwater fish, *Channa punctatus*", 2009, *Pest. Biochem. Physiol.* Vol. 94, 5-9.
- [39] F.R. De la Torre, A. Salibian, L. Ferrari, "Enzyme activities as biomarkers of freshwater pollution: Responses of fish branchial Na⁺K⁺-ATPase and liver transaminases", *Environ. Toxicol.* 1999, Vol. 14, 313-319.
- [40] F.R. De la Torre, A. Salibian, L. Ferrari, "Biomarkers assessment in juvenile *Cyprinus carpio* exposed to waterborne cadmium" *Environ. Poll.* 2000, Vol. 109, 277-282.
- [41] V. Palanivelu, K. Vijayavel, S. Ezhilarasibalasubramanian, M.P. Balasubramanian, "Influence of insecticidal derivative (Cartap Hydrochloride) from the marine polychaete in certain enzyme systems of the fresh water fish *Oreochromis mossambicus*", *J. Environ. Biol.* 2005, Vol. 26, 191-196.
- [42] M. Elumalai, M.P. Balasubramanian, "Influence of naphthalene on esterase activity during vitellogenesis of marine edible crab, *Scylla serrata*" *Bull. Environ. Contam. Toxicol.* 1999 Vol. 62, 743-748.
- [43] A. Yadav, A. Gopesh, R.S. Pandey, D.K. Rai, B. Sharma, "Fertilizer industry effluent induced biochemical changes in fresh water teleost, *Channa striatus* (Bloch)", *Bull. Environ. Contam. Toxicol.* 2007, Vol. 79, 588-595.
- [44] V.K. Mishra, M.K. Srivastava, R.B. Raizada, "Testicular toxicity in rat to repeated oral administration of tetramethyl thiuram disulfide (Thiram)", *Indian J. Exp. Biol.* 1998, Vol. 36, 390-394.
- [45] M. Alam, T. Frankel, "Gill ATPase of silver perch, *Bidyanus bidyanus*, and golden perch, *Macquaria ambigua*: effects of environmental salt and ammonia", *Aquaculture.* Vol. 251, 2006, 118-133.
- [46] S.D. McCormick, "Endocrine Control of Osmoregulation in Teleost Fish" *The Society for Integrative and Comparative Biology*, oxford Journals, Life Sciences. 2001, Vol. 41, 781-794.
- [47] S.D. McCormick, "Hormonal control of gill Na⁺K⁺-ATPase and chloride cell function", In: *Fish Physiology*, Vol. 14. Edited by C.M. Wood and T.J. Shuttleworth. Academic Press, San Diego. 1995, p. 285-315.
- [48] K. C. Chris, M. H. Wong, "Morphological and biochemical changes in the gills of *Tilapia* (*Oreochromis mossambicus*) to ambient cadmium exposure", *Aquat. Toxicol.* 2000, Vol. 48, 517-527.
- [49] S. Parvez, I. Sayeed, S. Raisuddin, "Decreased gill ATPase activities in the freshwater fish *Channa punctata* (Bloch) exposed to a diluted paper mill effluent", *Ecotoxicol. Environ. Saf.* 2006, Vol. 65, 62-66.
- [50] J. Thaker, J. Chhaya, S. Nuzhat, R. Mittal, "Effects of chromium (VI) on some ion-dependent ATPases in gills, kidney and intestine of a coastal teleost *Periophthalmus dipes*", *Toxicology.* 1996, Vol. 112, 237-244.
- [51] S.F. Perry, P. Laurent, "Environmental effects on fish gill structure and function: recent advances and future directions", In: Jensen, F., Rankin, C. (Eds.), *Fish Ecophysiology*. Chapman & Hall, London. 1993, 231-264.
- [52] A. K. Mishra, B. Mohanty, "Acute toxicity impacts of hexavalent chromium on behavior and histopathology of gill, kidney and liver of the freshwater fish", *Channa punctatus* (Bloch)", *Environ. Toxicol. Pharmacol.* Vol. 26, 2008, 136-141.
- [53] B.M. Alazemi, J.W. Lewis, E.B. Andrews, "Gill damage in the freshwater fish *Gnathonemus petersii* (family: Mormyridae) exposed to selected pollutants: an ultrastructural study", *Environ. Technol.* 1996, Vol. 17, 225-238.

AUTHORS

First Author – Remya Varadarajan, Research Scholar, Department of Marine Biology, Microbiology and Biochemistry, School of Marine Sciences, Cochin University of Science and Technology, Fine Arts Avenue, Cochin-16, Kerala, India. Email: remyavaradarajan@gmail.com.

Second Author – Hari Sankar. H.S, Research Scholar, Department of Marine Biology, Microbiology and Biochemistry, School of Marine Sciences, Cochin University of Science and Technology, Fine Arts Avenue, Cochin-16, Kerala, India. Email: harisankarhs@gmail.com

Third Author – Jisha Jose, Research Scholar, Department of Marine Biology, Microbiology and Biochemistry, School of Marine Sciences, Cochin University of Science and Technology, Fine Arts Avenue, Cochin-16, Kerala, India. Email: jishamariyak@gmail.com

Fourth Author – Babu Philip, Professor, Department of Marine Biology, Microbiology and Biochemistry, School of Marine Sciences, Cochin University of Science and Technology, Fine Arts Avenue, Cochin-16, Kerala, India. Email: drbabuphilip@gmail.com

Correspondence Author - Remya Varadarajan, Research Scholar, Department of Marine Biology, Microbiology and Biochemistry, School of Marine Sciences, Cochin University of Science and Technology, Fine Arts Avenue, Cochin-16, Kerala, India., Email:remyavaradarajan@gmail.com, remya_varada@yahoo.com , Mobile No. +91-9757088203