

# Case Report: Cystoid Macular Edema

## Effects of Eye Yogic Exercise & Alternative Medicine Therapies in Cystoid Macular Edema Patient

Kailash Mehra

MA Yoga, PG Diploma Naturopathy & Yoga, Fellowship In Pediatric Optometry, Director Preksha Eye Yoga a center for Vision Improvement, New Delhi.

DOI: 10.29322/IJSRP.12.02.2022.p12249  
<http://dx.doi.org/10.29322/IJSRP.12.02.2022.p12249>

Paper Received Date: 29th January 2022  
Paper Acceptance Date: 08th February 2022  
Paper Publication Date: 20th February 2022

**Abstract-** A 37 year old patient having gradual decrease in vision in left eye over six weeks with best corrected VA of 6/36 and 6/6 With and without pinhole glasses in left and right eye respectively. his peripheral vision was normal. edema and elevation of the macular area is seen on dilated fundus examination. OCT examination shows retinal elevation with multiple cystic spaces within the retinal layer. Flower petals appearance was clearly demonstrated under OCT with the average central foveal thickness measuring 295 $\mu$ m & 380.9 $\mu$ m, left and right eye, (see Figure 1) respectively, and his visual acuity was recorded 6/6 and 6/36 respectively (See figure 1). His right eye remain normal. A clinical diagnosis of CME on left eye was made. There is no history of other systematic illness. He was advised topical corticosteroids and non-steroidal anti-inflammatory, eye drops, and was suggested for left eye Intravitreal Ozurdex Implant. on his follow up after six weeks there were no significant improvement in his vision, and his average macular thickness worsen. (see Figure 2) then he was advised for alternative therapies. Later a dilated ocular examination was performed and started alternative therapies which includes, Eye yoga Exercise, Yoga, Shatkarma, Moxibustion and antioxidant diet rich in Vitamin A,C & E.

**Index Terms-** Cystoid macular edema, alternative therapy, reversal of eye disease, natural vision improvement program, eye exercise, alternative treatment for cystoid macular edema, preksha eye yoga

### I. INTRODUCTION

Cystoid Macular Edema (CME) is a leading cause of central vision loss in the world.<sup>1</sup> the disruption of the blood retinal barrier makes the retinal macula thicken. This causes leakage of fluid from perifoveal retinal capillaries and spread within the intracellular spaces of the retina, mainly in the outer plexiform layer visual loss from the retinal thickening and stored fluid distorts the architecture & shapes of photoreceptors.

The reported prevalence of DR in India ranges from 17.6% to 28.2% With this prevalence, and the number of cases increasing

day by day.<sup>2</sup> The economic and social burden of the disease demands a better way of effective screening strategies, accuracy in detection, and effective treatment for the same. Although There is not sufficient data available on the prevalence of management of CME separately.

In spite of advanced medical treatments in cataract surgery, cystoid macular edema is still one of the most common causes of poor visual acuity. topical non-steroidal, anti-inflammatory drugs, vascular endothelial growth factor (VEGF), and eye drops have been used since 1970 to prevent and reduce the CME<sup>3</sup> in many studies investigation found that this medication can improve CME gradually but it comes with the associated risk of developing a cataract. There are many risk factors which may affect the retinal environment.

India have 65 million diabetic adults, which is likely to increase to over 130 million by 2045. Vision impairment and blindness from diabetic retinopathy (DR), Cystoid macular edema and diabetic macular edema (DME) will increase unless systems and services are put in place to prevent & reduce the incidence of DR, CME and DME, and to increase access to diagnosis and effective treatment<sup>4</sup>. The potential economic and social burden of DM and DR demands definite needs for an effective screening strategy, accurate case detection, and treatment effective for both CME & retinopathy.

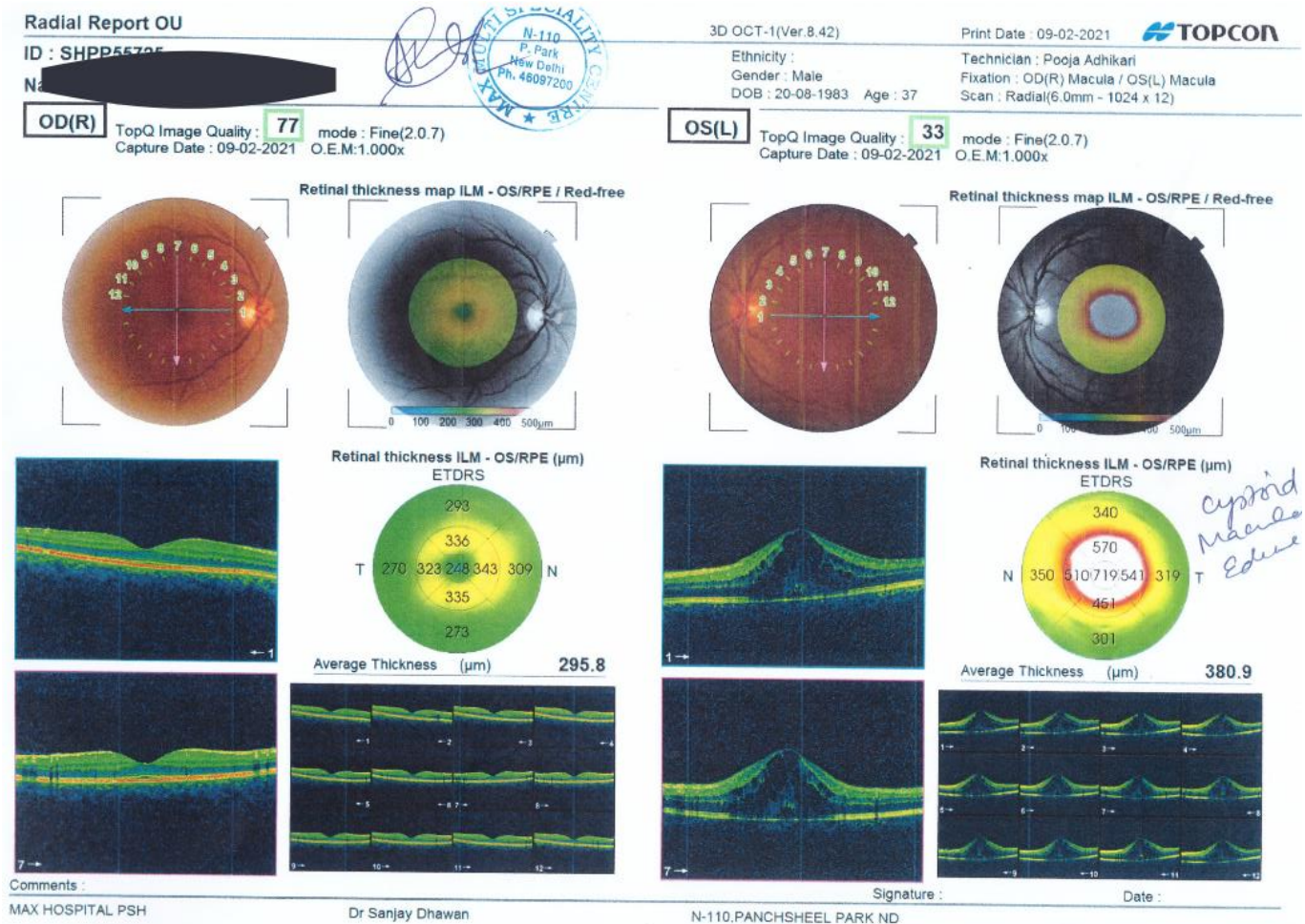
### II. CASE PRESENTATION

A 37-year-old man was suffering from a gradual decrease in vision in left eye over 6 months at the presentation. The best-corrected VA (visual acuity) was 6/36 with and without Pinhole glasses and 6/6 in the right eye. His peripheral vision was normal. excessive fluid accumulated within the macular retina so, he visited the doctor and found CME on angiography measuring 295  $\mu$ m and 380 $\mu$ m thickness by optical coherence tomography. OCT reports can be seen clearly abnormal fluid accumulated within the retina accompanied by retinal thickness (figure 1).

He was following the treatment with eye drops, topical corticosteroids and non-steroidal anti-inflammatory drugs. After

following the treatment for more than 6 weeks his vision and thickness did not improve. and he was advised for left eye

Intravitreal Ozurdex Implant<sup>5</sup>. One of his friends and our old patient told him about the Center for Vision Improvement. .



(figure 1)

Then, he visited Preksha Eye Yoga, a Center for vision improvement. After examined his reports and visual acuity. we designed alternative medicine therapy treatments which combine types of eye yogic exercises, acupressure therapy, hydrotherapy (Eyewash, steam, cold pack), moxibustion, & nutritional advice.

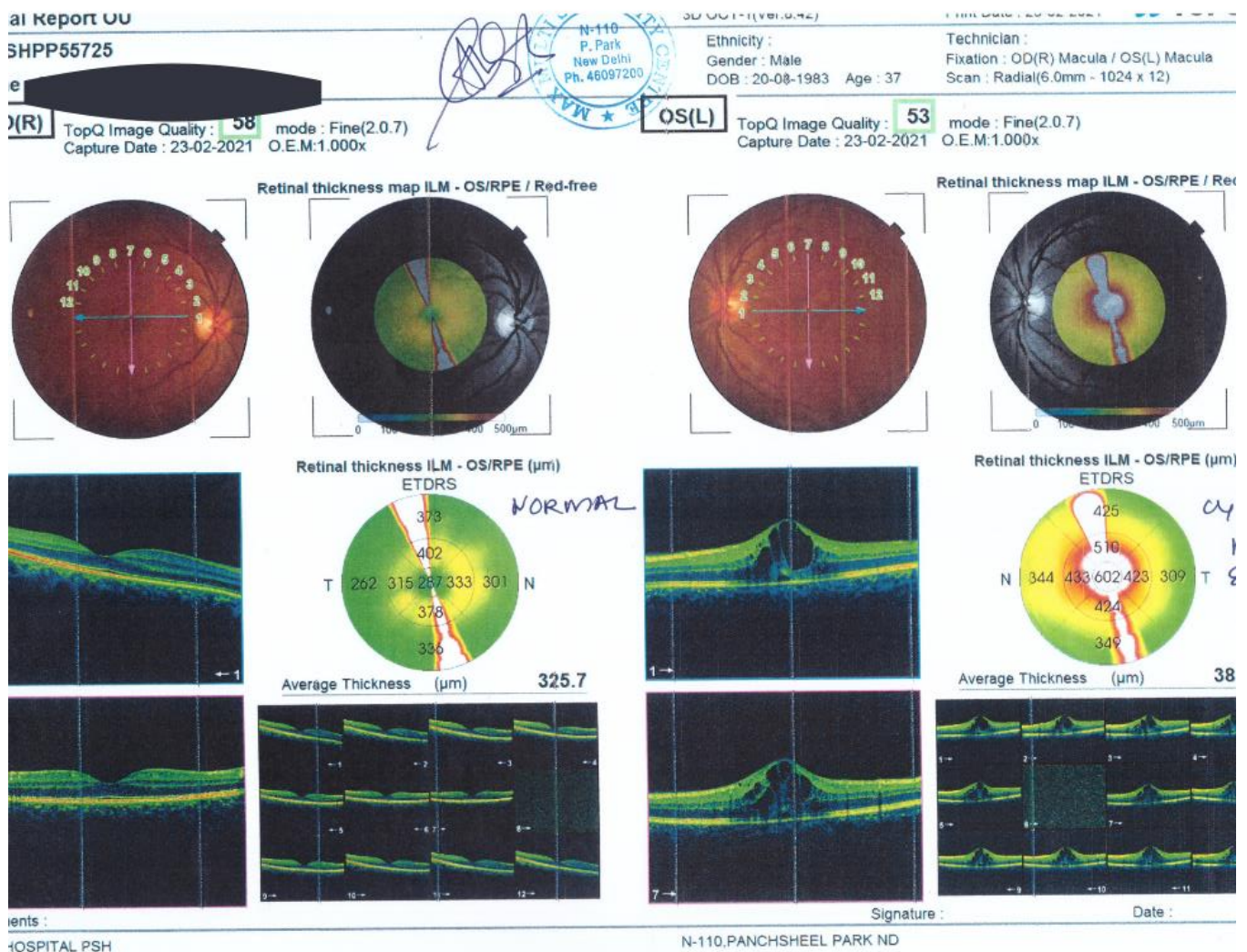
### III. DETAILED TREATMENT

The patient primarily receives honey eye detox then different types of eye yogic exercise are done with an Oculus Rotator, an innovative eye exercise device. It includes shoulder, neck & eye exercise so, we can reduce the stiffness of shoulder and neck muscles and stress from the optic nerve. Then in order to to promote blood circulation and release muscle tension acupressure was given (Zan Zhu Point (UB-2), Si Zhu Kong Point (SJ-23), Cheng Qi Point (ST-1), Yang Bai Point (GB-14), Yu Yao Point (Ex-HN4) ) which is followed by Moxibustion in the end.<sup>6</sup> All this treatment was continued daily upto 4 weeks. Moxibustion is a form of stimulation (heat therapy) in which dried plants material called moksha are burned very near the surface of the skin in order to increase blood circulation and improve the flow

of Qi in the body. Moxa stick made of mugwort, stinkweed, calotropis gigantea. These herbs are used because of its acrid, spicy odor which makes it travel through all of the meridians, regulate qi and blood, and expel cold by stimulation. It Stimulates circulation around the eye muscles. Moxa Expelled cold and dampness from the body by warming the meridians to relieve stress and strain from the optic nerve. after practicing for 4 weeks then OCT report shows improvement in visual acuity and decrease in Macular thickness. (see figure 3)

### IV. PRE-POST RESULTS

The subject was suffering from low (decreased) visual acuity and blurred vision in his left eye. his best visual acuity 6/36 with and without pinhole glasses (LE). Then he started practicing Preksha eye yoga treatment. After continuous practice for 4 weeks his vision shows Improvement in visual acuity and decrease in macular thickness measuring 295μm and 380.9μm



(Figure 2)

VA becomes 6/6 (LE). Macular OCT showed a reduction in the intraretinal edema of the left eye, and a significant reduction in the Central foveal thicknesses measured almost normal (figure 3). Systemically, the patient did not develop any new symptoms as a result of stopping exercises.

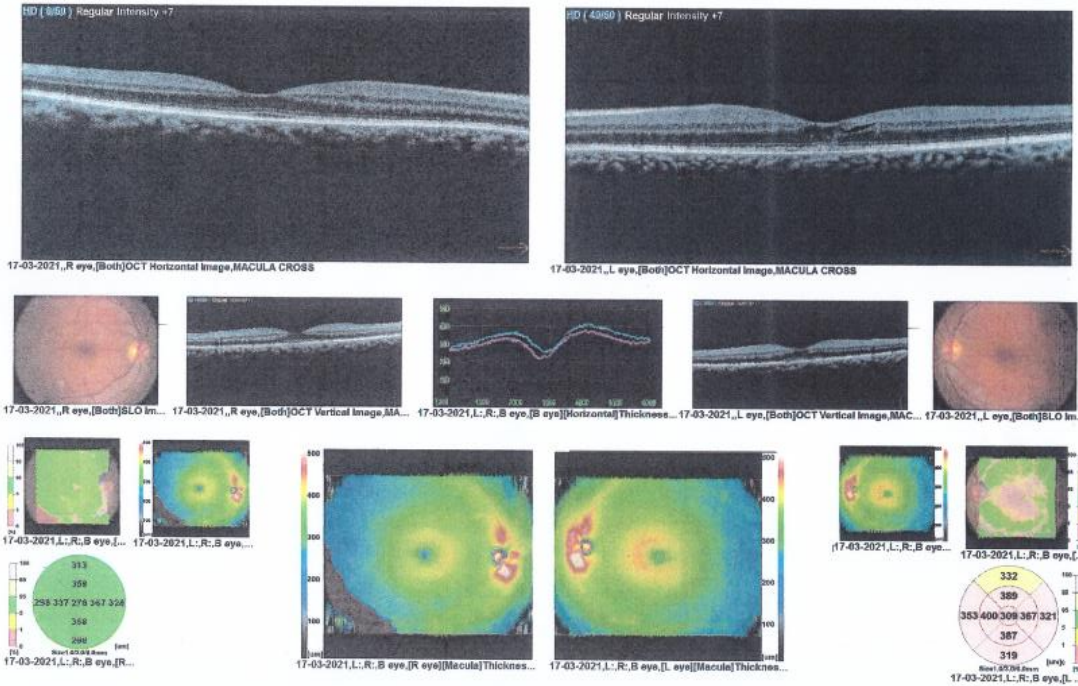
### V. OUTCOME AND FOLLOW-UP

At a review of his progress 3 weeks later, the patient reported a significant improvement in vision. His best corrected

**Max Eye Care**

Max Hospital Sushant Lok-1, Gurgaon  
 Ph.-0124-6623000

Name	[REDACTED]			ID	SHPP557255
BD	20-08-1983 (37year6month)	Date	17-03-2021	Sex	Male



2021/3/17\_NONE\_REPORT.

(figure 3)

**VI. DISCUSSION**

To the best of our knowledge, this is the first reported case of cystoid macular edema patients at Preksha Eye yoga, center for vision improvement. And we got the best results through Eye yogic exercise and alternative therapy. The alternative therapy approach heals the problem in a scientific manner. Shatkarma<sup>7</sup> and Jalneti<sup>8</sup> (neti) remove mucus and pollutants from the nasal passage and sinuses, allowing air to flow without obstruction. This helps relieve allergies, colds and sinusitis. Previous studies support the role of neti in treating in improving vision. Acupressure therapy<sup>9</sup> and diet<sup>10</sup>, management add to the results in management of eye related disorders. It can be a milestone in the field of alternative therapy options to improve vision naturally. As there are limited therapy options for CME<sup>11</sup>. It gives the patient hope that CME can be reversed naturally without any surgeries or side effects of the post-operative procedure. Further studies should be devoted to identifying the most effective strategy to prevent or reduce the CME and improvement in vision by alternative therapies. The efforts should include identifying the right nutrition, and a better alternative therapy management.

**ACKNOWLEDGEMENT**

This paper and the research behind it would not have been possible without the exceptional support of my Mentor **Dr. Viney Jain** Emeritus Professor Jain Vishva Bharati Institute (Deemed To Be University) His enthusiasm, motivation, knowledge and exacting attention to detail have been an inspiration and kept my work on track. My teacher Optom **Archana K. P.** Lecturer of Optometry at Malabar Institute of Optometry Kannur, has also looked over my manuscript and answered with patience numerous questions about the language and not only guided me, but unexpectedly shared the invaluable support in this case report. I am also grateful for the generosity and expertise of one and all who have improved this study in innumerable ways and saved me from many errors; those that inevitably remain are entirely my own responsibility.

**REFERENCES**

- [1] Gerwin B, Read RW, Taylor W. Rickettsial retinitis: acute unilateral vision loss with cystoid macular edema and stellate maculopathy. Retin Cases Brief Rep. 2011 Summer;5(3):219-22. doi: 10.1097/ICB.0b013e3181e180ff. PMID: 25390168.

- [2] Das T, Aurora A, Chhablani J, et al. Evidence-based review of diabetic macular edema management: Consensus statement on Indian treatment guidelines. *Indian J Ophthalmol.* 2016;64(1):14-25. doi:10.4103/0301-4738.178142
- [3] Walter K, Kauffman L, Hess J. Rate of pseudophakic cystoid macular edema using intraoperative and topical nonsteroidal antiinflammatory drugs alone without steroids. *J Cataract Refract Surg.* 2020 Mar;46(3):350-354. doi: 10.1097/j.jcrs.000000000000062. PMID: 32142038.
- [4] Gilbert C, Gordon I, Mukherjee CR, Govindhari V. Guidelines for the prevention and management of diabetic retinopathy and diabetic eye disease in India: A synopsis. *Indian J Ophthalmol.* 2020 Feb;68(Suppl 1):S63-S66. doi: 10.4103/ijo.IJO\_1917\_19. PMID: 31937733; PMCID: PMC7001190.
- [5] Garweg JG, Baglivo E, Freiberg FJ, Pfau M, Pfister IB, Michels S, Zandi S. Response of Postoperative and Chronic Uveitic Cystoid Macular Edema to a Dexamethasone-Based Intravitreal Implant (Ozurdex). *J Ocul Pharmacol Ther.* 2016 Sep;32(7):442-50. doi: 10.1089/jop.2016.0035. Epub 2016 Aug 1. PMID: 27479780.
- [6] Zhang WP, Onose Y, Fujikawa T. A Trial Study of Moxibustion with a Warming Needle on Edema. *J Acupunct Meridian Stud.* 2017 Jan;10(1):20-25. doi: 10.1016/j.jams.2016.12.008. Epub 2017 Jan 10. PMID: 28254097.
- [7] Swathi PS, Raghavendra BR, Saoji AA. Health and therapeutic benefits of Shatkarma: A narrative review of scientific studies. *J Ayurveda Integr Med.* 2021 Jan-Mar;12(1):206-212. doi: 10.1016/j.jaim.2020.11.008. Epub 2021 Jan 13. PMID: 33454186; PMCID: PMC8039332.
- [8] Meera S, Vandana Rani M, Sreedhar C, Robin DT. A review on the therapeutic effects of NetiKriya with special reference to JalaNeti. *J Ayurveda Integr Med.* 2020 Apr-Jun;11(2):185-189. doi: 10.1016/j.jaim.2018.06.006. Epub 2019 Jan 5. PMID: 30616871; PMCID: PMC7329727.
- [9] Gao H, Zhang L, Liu J. Auricular acupressure for myopia in children and adolescents: A systematic review. *Complement Ther Clin Pract.* 2020 Feb;38:101067. doi: 10.1016/j.ctcp.2019.101067. Epub 2019 Oct 24. PMID: 31672461.
- [10] Lawrenson JG, Downie LE. Nutrition and Eye Health. *Nutrients.* 2019 Sep 6;11(9):2123. doi: 10.3390/nu11092123. PMID: 31489894; PMCID: PMC6771137.
- [11] Choi JY, Buzney SM, Weiter JJ. Cystoid macular edema: current modes of therapy. *Int Ophthalmol Clin.* 2005 Fall;45(4):143-51. doi: 10.1097/01.iio.0000176354.56990.f5. PMID: 16199973.

#### AUTHORS

**First Author** – Kailash Mehra, MA Yoga, PG Diploma Naturopathy & Yoga, Fellowship In Pediatric Optometry, Director Preksha Eye Yoga a center for Vision Improvement, New Delhi.