

# Cytomegalovirus meningoencephalitis in an immunocompetent patient: a case report

Rim Tazi el pardya\*, Zakaria Salimi\*\*, Jehanne Aasfara\*\*\*

Neurology, Mohamed VI University of Health Sciences, Faculty of Medicine, Cheikh Khalifa Ibn Zayed hospital, Casablanca, MAR

DOI: 10.29322/IJSRP.12.02.2022.p12213  
<http://dx.doi.org/10.29322/IJSRP.12.02.2022.p12213>

**Abstract-** Cytomegalovirus (CMV) is a DNA virus that belongs to the  $\beta$ -Herpesvirinae family. It causes asymptomatic infection in immunocompetent adults. The affection of the central nervous system by CMV in immunocompetent patients is uncommon. We reported a case of CMV meningoencephalitis in an immunocompetent 17-year-old patient with no history. The brain MRI shows hyperintensity in the right and the left temporal regions. The detection of cytomegalovirus (CMV) in *cerebrospinal fluid* (CSF) was performed by the technique of *polymerase chain reaction* (PCR). The patient was treated by Ganciclovir with good clinical improvement. After six months, the control of the HIV serology was negative and there was no history of any immunosuppressive therapy.

**Index Terms-** Cytomegalovirus, meningoencephalitis, immunocompetent patient, Ganciclovir.

## I. INTRODUCTION

Cytomegalovirus (CMV) induces asymptomatic infections in immunocompetent adults. The most common clinical presentations of the central nervous system are encephalitis,

meningitis, myelitis, and peripheral neuropathies. (1) In the literature, CMV meningoencephalitis has been principally reported in immunocompromised patients. (1) We described the case of CMV meningoencephalitis in an immunocompetent patient. The diagnosis was confirmed by CMV-PCR in the cerebrospinal fluid (CSF) analysis. The good clinical improvement was remarkable after taking the Ganciclovir.

## II. CASE PRESENTATION

We reported the case of 17 years old woman, who had a cough, chest pain, and general weakness. After one week, she developed headache, nausea, and fever and then was admitted to the emergency for a convulsive status epilepticus. The neurological examination after the onset found a meningeal syndrome with no focal neurological signs. Cranial magnetic resonance imaging (MRI) showed cortical bilateral temporal signal abnormalities.(figure 1) Cerebrospinal Fluid (CSF) examination revealed a pleocytosis of 22 cells/mm<sup>3</sup> (2% neutrophils and 98% lymphocytes) and CSF glucose and protein levels were normal.

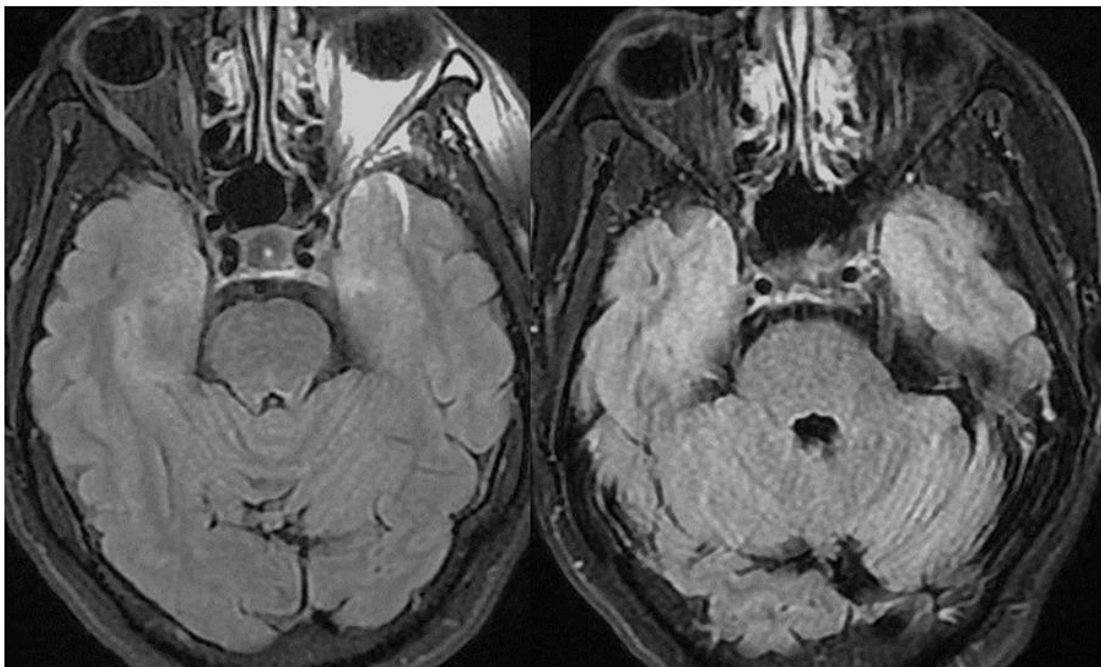


Figure 1: MRI FLAIR sequence showed diffuse cortical swelling in the right and the left temporal regions.

These results suggested a Herpes meningoencephalitis and IV Acyclovir was started along with Levetiracetam. The patient was seizure-free within 24 hours but still had a high fever. A second cerebrospinal fluid (CSF) showed meningitis with 150 cells/mm<sup>3</sup> (2% neutrophils and 98% lymphocytes) and normal levels of glucose and protein. CSF culture and microscopy were negative.

Cryptococcus neoformans, Herpes simplex virus (HSV), varicella-zoster (VZV), and Epstein-Barr virus (EBV) antigens were not found in the cerebrospinal fluid but the CMV antigen was detected by PCR at a significant rate. The viral serologies VIH, hepatitis, and syphilis were negative. The patient was treated with Ganciclovir 300 mg twice a day for 21 days. She clinically improved and the fever goes down. After 6 months, the check-up of VIH serology was negative. We concluded To a CMV meningoencephalitis in an immunocompetent patient.

### III. DISCUSSION

CMV is a double-stranded DNA virus and belongs to the Herpesviridae family. It is a ubiquitous virus that contaminates almost all individuals who have mainly a positive serology. Primary infection is asymptomatic in immunocompetent patients but may cause flu-like symptoms. However, the seropositivity of CMV in the immunocompromised host is a poor prognostic factor; especially those with HIV, organ transplantation, or those under Immunosuppressive therapy. (1) Cytomegalovirus (CMV) can affect different sites in immunocompetent hosts notably the central nervous system. (1) We reported the case of CMV meningoencephalitis in immunocompetent young adults. It is a rare entity that has a variety of clinical manifestations as cognitive decline, confusion, cranial nerve palsies. Our patient was admitted with generalized epileptic seizures. Maschio et al suggest that CMV can cause alterations in neuronal calcium metabolism leading to epileptic discharges. (2) The highly sensitive PCR in CSF is the right method to confirm the diagnosis of CMV meningoencephalitis. (3) In the review of literature, Sarah M et al found a typical aspect in the brain MRI; it's an increased T2/FLAIR signal in the cerebral white matter. The brain MRI of our patient, reveals the same aspect affecting the right and left temporal area. The immunocompetence status of our patient is uncommon in CMV infection. The investigations for underlying immunosuppression were negative, especially the HIV serology. We noticed that Anti-CMV IgG antibodies were detected. The hypothesis that may explain this clinical course, is that the virus was present in latent form, reactivated by a triggering event notably the respiratory infection. (4) In the literature, only some cases of CMV meningoencephalitis in immunocompetent patients were reported. The ganciclovir is recommended as first-line treatment for severe CMV in immunocompromised adults (5). Ganciclovir is a Nucleoside analog that damages DNA polymerases and produces chain termination (5). Several studies emphasize the importance of the morbi-mortality

associated with untreated CMV infection in immunocompetent patients. Thus they report rapid clinical improvement after taking Ganciclovir. (6) It's was the case in our patient after 21 days of the antiretroviral treatment.

### IV. CONCLUSION

In summary, we should think about CMV in meningitis in an immunocompetent patient and serologic testing for CMV should be done to prevent clinical complications. We also conclude that CMV meningoencephalitis can occur with positive cerebrospinal fluid CMV PCR and negative serum CMV PCR that may be explained by CMV reactivation in immunocompetent patients with latent infection triggered by a critical illness.

### ACKNOWLEDGMENT

Aasfara has played a substantial role in designing the article. Rim Tazi, principal and corresponding author, has played an important role in redaction and literature search. Zakaria Salimi, a co-author, has carried out a revision of the text.

### REFERENCES

- [1] S A Ross 1, Z Novak, S Pati: Overview of the diagnosis of cytomegalovirus infection. *Infect Disord Drug Targets*. 2011, 11(5):466-74. 10.2174/187152611797636703
- [2] M. Maschio • F. Giudiceandrea • P. Contadini: Cytomegalovirus encephalitis: diagnosis with clinical approach, EEG and PCR techniques. *Ital J Neurol Sci*. 1999, 20:255-258. 10.1007/s100720050041
- [3] S.Micallef, R.Galea: CMV encephalitis in an immune-competent patient. *BMJ Case Rep*. 2018, 22:47-40. 10.1136/bcr-2018-224740
- [4] W D Döcke 1, S Prösch, E Fietze: Cytomegalovirus reactivation and tumour necrosis factor. *Lancet* . 1994, 343(8892):268-9. 10.1016/s0140-6736(94)91116-9
- [5] Y.Guo, L.Jiang: Cytomegalovirus encephalitis in immunocompetent infants: A 15-year retrospective study at a single center. *Int J Infect Dis* . 2019, 82:106-110. 10.1016/j.ijid.2019.02.045
- [6] M Eddleston 1, S Peacock: Severe cytomegalovirus infection in immunocompetent patients. *Clin Infect Dis*. 1997, 24(1):52-6. 10.1093/clindis/24.1.52

### AUTHORS

**First Author** – Rim Tazi El Pardya , Neurologist , Mohamed VI University of Health Sciences, Faculty of Medicine, Cheikh Khalifa Ibn Zayed hospital, Casablanca, MAR, rimouchi6491@gmail.com

**Second Author** – Zakaria Salimi, Neurologist, Mohamed VI University of Health Sciences, Faculty of Medicine, Cheikh Khalifa Ibn Zayed hospital, Casablanca, MAR, dr.salimizakaria@gmail.com

**Third Author** – Jehanne Aasfara, Neurologist, Mohamed VI University of Health Sciences, Faculty of Medicine, Cheikh Khalifa Ibn Zayed hospital, Casablanca, MAR, jaasfara@gmail.com

