

# Accessory Mental Foramen : A Case Report

Amiyaranjan Sahoo<sup>3</sup>, Ramanupam Tripathy<sup>1</sup>, Subrat Kumar Padhiary<sup>2</sup>, Sudipta Sahu<sup>3</sup>

<sup>1</sup> Professor , Department of oral & maxillofacial surgery, IDS ,Bhubaneswar

<sup>2</sup> Reader, Department of oral & maxillofacial surgery, IDS ,Bhubaneswar

<sup>3</sup> PG Student , Department of oral & maxillofacial surgery,IDS ,Bhubaneswar

**Abstract-** Accessory mental foramen is a rare anatomical variation. Even so, in order to avoid neurovascular complications, particular attention should be paid to the possible occurrence of one or more accessory mental foramen during surgical procedures involving the mandible.

**Index Terms-** Mental nerve, accessory mental foramen, trauma

## I. INTRODUCTION

Confirmation of the mandibular canal course, which carries the inferior alveolar nerve, artery, and vein, is clinically important to avoid local injury to the nerve during surgical procedures. Especially, it is crucial to identify the anatomic location of the mental foramen (MF) and mandibular canal in relation to the root apices of the premolars and molars<sup>(1,2,3)</sup>. Neurovascular bundles of the supraorbital, infraorbital, and mental foramina are important structures that need to be considered in local anesthesia and surgical procedures in the maxillofacial area. An understanding of the anatomy of the location of these foramina is essential for performing effective nerve block and avoiding injuries to the neurovascular bundles<sup>(4)</sup>.

The presence of small foramina identified as accessory mental foramina (AMF) in the surrounding area of the mental foramen has been discovered<sup>(5,6)</sup>. The reported frequency of occurrence of AMF has varied between less than 5% and about 30%<sup>(7-11)</sup>. Concepcion et al.<sup>(12)</sup> encountered an accessory branch of mental nerve adjacent to the MF during flap reflection in a periapical surgery. Çag~i-rankaya et al<sup>(13)</sup> presented a case of AMF below the apex of the first molar demonstrated with intraoral radiographies for periodontal treatment.

Toh et al<sup>(14)</sup> described the distributions of accessory mental nerve emerging from the AMF to the mucous membrane and skin of the corner of mouth to the labial region. The group indicated the possible occurrence of pain caused by injury of the nerves emerging from the AMF by an injection via the mucous membrane. Boronat López et al<sup>(15)</sup> mentioned the AMF as one of the factors implicated in regional anesthesia failure.

AMF can be rarely observed with intraoral and panoramic radiography because the size is generally less than 1.0 mm<sup>(14)</sup>.

## II. CASE REPORT

A 20 years old male patient was referred to Department of Oral & Maxillofacial Surgery, Institute of Dental sciences, Bhubaneswar, Odisha, with a history of road traffic accident and sustained facial injury with no other systemic problems.

Clinical examination revealed swelling in the bilateral para symphysis region, which was tender on palpation, step deformity was present in the lower border of the mandible bilaterally. Intra oral examination revealed to have deranged occlusion, and step deformity of alveolar segments were seen between left premolars and molars and right canine premolar region. The fracture fragment was displaced downwards & buccally leading to anterior open bite. The medical history of the patient was noncontributory. Panoramic radiograph showed a fracture lines above mentioned with impaction of the fracture fragments. After clinical and radiographic evaluation the case was diagnosed as bilateral parasymphysis fracture of the mandible.(FIG 1)

The operation procedure was planned as open reduction and internal fixation under general anesthesia, during the vestibular de gloving incision which was extended to expose the fracture site, the AMF was accidentally discovered and noted (FIG 2). Point to be noted is this AMF was not radio graphically differential on the orthopantomogram hence it was reported as a rare finding. The case was operated and open reduction internal fixation using miniplates was done to stabilize the fractured mandible.(FIG 3 & 4)

## III. DISCUSSION

A few studies reported the existence of a mental-incisive foramen complex, which was apparently similar to but distinct from the AMF in this respect that no intra osseous canals were found between the MF<sup>(16,17)</sup>. In the osteologic and gross investigations, the diameter of MF ranged from 2.38 –2.64 mm<sup>(18)</sup>, whereas that of AMF ranged from 0.74 – 0.89 mm<sup>(14)</sup>. In a study, most of the AMF were obviously smaller than MF; hence, discrimination between the two was not difficult<sup>(19)</sup>.

Commonly, 3 branches of the mental nerve emerge from the MF<sup>(20,21)</sup>. One of them innervates the skin of the mental area, where as the others spread to the skin of the lower lip, oral mucosa, and gingival as far posterior as the second premolar. Hu et al.<sup>(22)</sup> categorized the mental nerve into 4 terminal branches as angular, medial inferior labial, lateral inferior labial, and mental branches, which originated from 3 or 2 main branches emerging from the MF. The position of the AMF was influenced by the branched site and length of the accessory branch. The variance of the relative position of the AMF to MF was greater in the horizontal direction than in the vertical direction<sup>(19)</sup>.

In another study no absence of mental foramen was observed single mental foramen was seen in most mandibles— 108 (98.2%) on both sides. Two specimens (1.8%) had double mental foramina. For the mental foramen, the distances to midline were 2.80 cm in average on the right and 2.78 cm on the left. The average distances to the inferior rim of the mandible on

the right and left were 1.45 and 1.44 cm. exit from the MF<sup>(4)</sup>. Therefore, damage to these terminal branches of the mental nerve can, on occasion, cause loss of sensation to the lower anterior teeth<sup>(23)</sup>.

Saywer et al<sup>(9)</sup> accessed the occurrence of additional foramen (AMF) in four population groups

1. American whites-1.4%
2. Asian Indians-1.5%
3. African Americans-5.7%
4. Pre colombiannazca Indians-9%

The mental foramen is an important landmark when considering placing implants in the foraminal region of mandibular arch. Differences in its location, number of foramina, and the possibility that an anterior loop of the mental nerve may be present mesial to the mental foramen need to be considered prior to preparing an osteotomy in this region<sup>(24)</sup>.

It was thus considered that the accessory branch of the mandibular canal connecting the mandibular canal to the AMF is rarely injured because both the MF and mandibular canal are noted to prevent surgical injury.

DECLARATION: No funding or conflict of interest declared whatsoever.

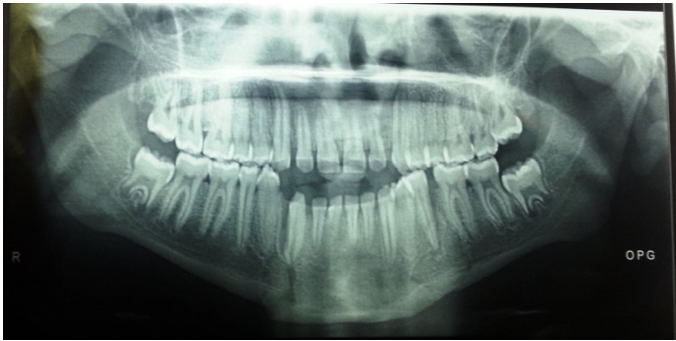

Fig 1

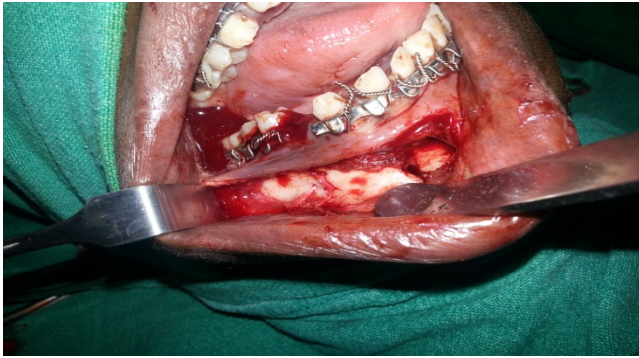


Fig 2

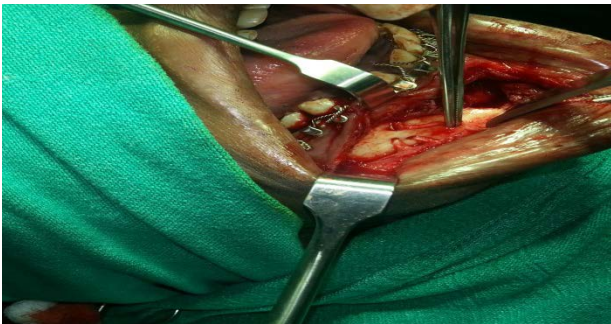


Fig 3

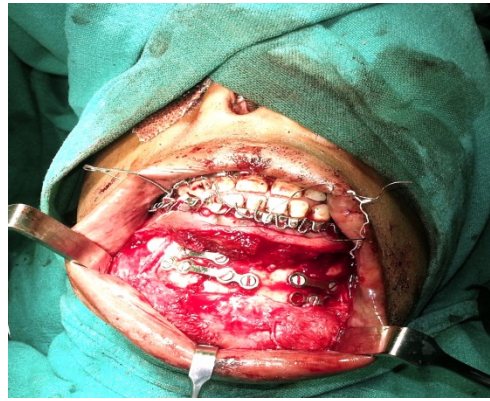

Fig 4

Fig 1: pre operative OPG

FIG 2 : accessory mental foramen

FIG 3 : reduction preserving the mental nerve

Fig 4 : final internal fixation preserving mental nerve

#### REFERENCES

- [1] Moiseiwitsch JR. Avoiding the mental foramen during periapical surgery. *J Endod* 1995;21:340–2.
- [2] Phillips JL, Weller RN, Kulild JC. The mental foramen: 3—size and position on panoramic radiographs. *J Endod* 1992;18:383–6.
- [3] Phillips JL, Weller RN, Kulild JC. The mental foramen: 1—size, orientation, and positional relationship to the mandibular second premolar. *J Endod* 1990;16:221–3.
- [4] Sithiporn Agthong, MD, PhD, Thanasilp Huanmanop, MD, and Vilai Chentanez, MD, PhD *J Oral Maxillofac Surg* 63:800-804, 2005
- [5] Riesenfeld A. Multiple infraorbital, ethmoidal, and mental foramina in the races of man. *Am J Phys Anthrop* 1956;14:85–100.
- [6] Sutton RN. The practical significance of mandibular accessory foramina. *Aust Dent J* 1974;19:167–73.
- [7] Agthong S, Huanmanop T, Chentaez V. Anatomical variations of the supraorbital, infraorbital, and mental foramina related to gender and side. *J Oral Maxillofac Surg* 2005;63:800–4.
- [8] Hanihara T, Ishida H. Frequency variations of discrete cranial traits in major human populations: vessel and nerve related variations. *J Anat* 2001;199:273–87.
- [9] Sawyer DR, Kiely ML, Pyle MA. The frequency of accessory mental foramina in four ethnic groups. *Arch Oral Biol* 1998;43:417–20.
- [10] Wesley ES. The position of the mental foramen in Asian Indians. *J Oral Implantol* 1994;20:118–23.
- [11] Gershenson A, Nathan H, Luchansky E. Mental foramen and mental nerve: changes with age. *Acta Anat* 1986;126:21–8.
- [12] Concepcion M, Rankow HJ. Accessory branch of the mental nerve. *J Endod* 2000;26:619–20.
- [13] Çağırankaya LB, Kansu H. An accessory mental foramen: a case report. *J Contemp Dent Pract* 2008;9:98–104.
- [14] Toh H, Kodama J, Ohmori T. Anatomical study of the accessory mental foramen and the distribution of its nerve. *Okajimas Folia Anat* 1992;69:85–8.
- [15] Boronat López A, Peñarrocha Diago M. Failure of locoregional anesthesia in dental practice: review of the literature. *Med Oral Patol Oral Cir Bucal* 2006;11:E510–3.
- [16] Kieser J, Kuzmanovic D, Payne A, Dennison J, Herbison P. Patterns of emergence of the human mental nerve. *Arch Oral Biol* 2002;47:743–7.
- [17] Serman NJ. The mandibular incisive foramen. *J Anat* 1989;167:195–8.
- [18] Oguz O, Bozkir MG. Evaluation of location of mandibular and mental foramina in dry, young, adult human male, dentulous mandibles. *J West Indian Med* 2002;51:14–6.
- [19] Kaori Katakami, DDS, PhD, Akira Mishima, AT, Kazunari Shiozaki, DDS, PhD, Shinji Shimoda, DDS, PhD, Yoshiki Hamada, DDS, PhD,§ and Kaoru Kobayashi, DDS, PhD\*, American Association of Endodontists.
- [20] Sicher H, Dubrul EL. *Oral anatomy*. 6th ed. Saint Louis: Mosby Comp, 1975:392.
- [21] Williams PL, Warwick R, Dyson M, Bannister LH. *Gray's anatomy*. 37th ed. Edinburgh and New York: Churchill Livingstone, 1989:1106.
- [22] Hu KS, Yun HS, Hur MS, Kwon HJ, Abe S, Kim HJ. Branching patterns and intraosseous course of the mental nerve. *J Oral Maxillofac Surg* 2007;65:2288–94.
- [23] Pogrel MA, Smith R, Ahani R. Innervation of the mandible incisors by the mental nerve. *J Oral Maxillofac Surg* 55:961. 1997
- [24] Gary Greenstein, Dennis Tarnow, *J Periodontol* 2006;77:1933-1943.

#### AUTHORS

**First Author** – Ramanupam Tripathy-Professor , Department of oral & maxillofacial surgery,IDS ,Bhubaneswar (ramanupam@gmail.com)

**Second Author** – Subrat Kumar Padhiary-Reader, , Department of oral & maxillofacial surgery,IDS ,Bhubaneswar (subratkumarpadhiary@gmail.com)

**Third Author** – Amiya Ranjan Sahoo-PG Student , Department of oral & maxillofacial surgery,IDS ,Bhubaneswar (dr.amiyaranjansahoo@gmail.com)

**Fourth Author** – Sudipta Sahu- PG Student , Department of oral & maxillofacial surgery,IDS ,Bhubaneswar (drsudiptosahu@gmail.com) (corresponding author)