Histological Observations on the Infundibulum of Kuttanad Duck (Anas platyrhynchos domestics) during Postnatal Period

Patki H. S[*], Lucy K. M[**], Chungath J. J[**]

[*] Part of MVSc Thesis submitted to Kerala Agricultural University, Thrissur, Kerala
[**] Department of Veterinary Anatomy and Histology, College of Veterinary and Animal Sciences, Kerala Veterinary and Animal Sciences University, Mannuthy, Thrissur -680 651, Kerala.

Abstract- Postnatal histological development of infundibulum of the oviduct in the Kuttanad duck (Anas Platyrhynchos domesticus) was studied using 78 ducks in different stages of development from day-old to 24th week of age. In the day-old ducklings, the cranial end of the undifferentiated oviduct corresponded to the infundibulum with no distinct differentiation into different tunics. At 12th week of age, tubular glands first appeared in the lamina propria of the neck region which was accompanied by ciliogenesis. Goblet cells increased in number in the lining epithelium of the caudal most region of the neck of the infundibulum, at 24th week of age. At this age, the proprial glands in the neck of the infundibulum were large in diameter, which increased in number as well as width gradually and attained maximum width. In all the age groups, lamina propria of the funnel region of the infundibulum was devoid of any glands and the mucosal folds in the funnel were shorter than that of neck region. Tunica mucosa occupied the maximum thickness followed by the tunica muscularis and tunica serosa respectively.

Index Terms- Postnatal development, Histology, Infundibulum, Oviduct and Kuttanad duck

I. Introduction

Kerala is the home tract for Kuttanad breed of ducks which are well known for their attractive egg size and high disease resistance (Jalaludeen *et al.*, 2004). In order to ensure persistent and maximum production and to evolve better managemental practices, it is essential to have in depth knowledge on the developmental aspects of the reproductive tract. In birds, infundibulum plays key functional role in capture and transfer of ovum as well as in formation of chalazae. In general it consisted of two regions *viz.*, a wide slit like funnel region cranially which continues as tubular neck region caudally. Although investigations encompassing gross as well as histological aspects have been conducted on the infundibulum of the oviduct in wide variety of birds including domestic fowl (Aitken and Johnston, 1963; Hodges, 1974; King, 1975 and Nickel *et al.*, 1977), Japanese quail (Lucy and Harshan, 1999) and turkey and pigeon (Mohammadpour and Keshtmandi, 2008), information regarding the developmental changes in the histomorphology of the infundibulum in Kuttanad duck is scanty. Hence, the present work was undertaken to envisage the age related changes in the infundibulum with respect to its histoarchitecture during postnatal period in Kuttanad ducks.

II. Materials and Methods

In all, 78 Kuttanad ducks were used for the present study. The birds were selected randomly from a single hatch and reared at the University Poultry Farm, Mannuthy under semi- intensive system of management. Feed and water were provided *ad lib*. The study was carried out in birds of different age groups, ranging from day-old to 24 weeks. The material was collected from six birds in each group at fortnightly intervals.

After recoding the gross features, the material was fixed in neutral buffered formalin. Different segments of the oviduct were processed and paraffin sections of 5µm thickness were taken for histological studies. Routine staining technique such as Haematoxylin and Eosin staining method as described by Luna (1968) was followed. Micrometric observations were done by using ocular micrometer.

III. RESULTS AND DISCUSSION

In the day-old ducklings, the cranial end of the undifferentiated oviduct corresponded to the infundibulum and consisted of the innermost epithelium and subepithelial tissue (Fig. 1). The oviduct wall was not differentiated into different tunics distinctly. The lumen was flanked by characteristic low mucosal folds which were lined by simple columnar epithelium. The total number of mucosal folds was in the range of 10 to12. Caudally number of folds increased upto 16 to 18. The sub-epithelial connective tissue was made up of densely packed cells with fine collagen fibres and was rich in capillaries. Both dorsal as well as ventral ligaments were attached to the oviduct and were abundantly supplied by blood vessels. Ventral ligament showed the presence of smooth muscle fibres (Fig. 2). These observations are in accordance with the observations made by Lucy and Harshan (1999) in Japanese quail.

At two weeks of age, the secondary mucosal folds started appearing in the cranial end of the undifferentiated oviduct corresponding to the infundibulum. By 6th week, a very thin tunica muscularis appeared as a single layer. At 12th week of age, tubular glands first appeared in the lamina propria of the neck region (Fig.3). In Japanese quail, glands could be first located at the age of 40 days (Lucy and Harshan, 1999).

Ciliogenesis in the infundibulum began at this age and the lining epithelium also showed presence of few non-ciliated glandular cells and occasional vacuolation. Such extensive ciliation was also noticed by Mohammadpour and Keshtmandi (2008) who speculated that, the rhythmic beating of these cilia and the gross oblique arrangement of the mucosal folds created a vortex to pull and transport the egg. At 14th week, neck region of the infundibulum showed rapid development of the mucosal folds into primary, secondary and tertiary folds with consequent increase in their height and width. Total number of mucosal folds was about 15 to 16. At this stage funnel region also showed development of secondary folds (Fig. 4). However, the mucosal folds in the funnel were shorter than that of neck region. Tunica muscularis of infundibulum was thinner than more caudal segments of the oviduct.

In the adult Kuttanad duck (20 weeks of age), there were four types of epithelial cells in the mucosa of infundibulum namely predominant non-secretory ciliated cells; non-ciliated mucous-secreting goblet cells found in between the ciliated cells; secretory cells other than goblet cells which were located in the glandular grooves and lining cells of the tubular glands of the caudal region of the infundibulum (Figs. 5 and 6). These results are in total agreement with those of Aitken and Johnston (1963) in domestic fowl. Lamina propria of the funnel region of the infundibulum was devoid of any glands and contained collagen fibres along with fine reticular and a few elastic fibres as reported by Lucy and Harshan (1999) in Japanese quail.

In differentiated oviduct, the lining epithelium at the opening of the lips of the funnel was low columnar ciliated type which rapidly changed into tall ciliated columnar in the distal funnel and neck of the infundibulum. Similar observations were also made in pigeon by Dominic (1960) and Hodges (1974) in domestic fowl.

Ciliated cells possessed oval nuclei lying at or above the centre of the cell. Goblet cells showed a basal nucleus and apical granular cytoplasm. Similar findings were also documented by Hodges (1974) and Naragude *et al.* (1999) in domestic fowl, Lucy and Harshan (1999) in Japanese quail and Moraes *et al.* (2007) in nothura spotted quail and Das and Biswal (1968), Rao (1994) and Ozen *et al.* (2009) in duck.

The formation of tubular glands was in accordance with observations made by Bradley and Grahame (1960) in domestic fowl. In the neck of the infundibulum the more complex mucosal folds with deeper glandular grooves eventually gave rise to small tubular glands from their corners (Fig. 6). The deeper regions of the mucosal folds where the transformation of glandular grooves into tubular glands occurred, the lining cells lacked cilia and were cuboidal with eosinophilic supranuclear cytoplasm. The proprial glands were lined by cuboidal to columnar cells with indistinct boundaries, basally located light stained round nuclei, eosinophilic supranuclear cytoplasm and enclosed a large lumen. The proprial glands in the neck of the infundibulum were large in diameter, which increased in number as well as width gradually and attained maximum width at 24th week of age (Fig. 7). In the caudal most region of the neck of the infundibulum, goblet cells increased in number in the lining epithelium (Fig. 8).

The funnel region showed mainly primary mucosal folds with some secondary folds. The depth of longitudinally oriented low mucosal folds appeared to increase as the funnel approached the neck region whereas within the neck of the infundibulum, the spirally oriented longitudinal folds increased in depth and gave rise to numerous secondary and tertiary folds. Among different segments of the oviduct, the infundibulum showed the least height and width of mucosal folds throughout the postnatal period. Similar observations were also made by Khokhlov and Kuznetcov (2007) in the domestic fowl.

Different micrometric parameters of the Infundibulum of the oviduct in Kuttanad Duck at 12th, 18th and 24th week of age are as shown in table1. The mucosal folds in the funnel were shorter than that of neck region.

The muscular tunic of the neck region was thicker than that of the funnel and was differentiated into ill defined inner circular and outer longitudinal muscle bundles (Fig. 9). At the infundibulum-magnum junction, both the mucosal and muscular layers increased in thickness and structural complexity. These results are in total agreement with those of Hodges (1974) and Gilbert (1979) in domestic fowl and Lucy and Harshan (1999) in Japanese quail. The collagenous serosal tunic was found to be thin with folds, blood vessels and nervous plexuses. Distinct serosal tunic was visible only in adult birds (Fig. 9).

In adult birds, analysis of the wall of the infundibulum revealed that tunica mucosa occupied the maximum thickness (81%) followed by the tunica muscularis (16%) and tunica serosa (3%). In domestic fowl, as reported by Khokhlov (2008), similar relationship between percentage contribution of different tunics was observed except the fact that tunica mucosa was comparatively thinner (64%).

REFERENCES

[1] Aitken, R. N. C. and Johnston, H. S. 1963. Observations on the fine structure of the infundibulum of the avian oviduct. *J. Anat.* 97: 87-89.

[2] Bradley, O. C. and Grahame, T. 1960. *The Structure of the Fowl.* Oliver and Boyd, Edinburgh, 155p.

[3] Das, L. N. and Biswal, G. 1968. Microanatomy of the reproductive tract of domestic duck (*Anas boschas*). *Indian Vet. J.* 45:1003-1009.

[4] Dominic, C. J. 1960. The secretory activity of the funnel of the avian oviduct. *Current Sci.* 29: 274-275.

[5] Gilbert, A. B. 1979. Female Genital Organs. In: *Form and Function in Birds*. A. S. King and J. Mc Lelland (Eds.). Academic Press, New York, pp. 237-360.

[6] Hodges, R. D. 1974. *The Histology of the Fowl*. Academic Press, London, 648p.

[7] Jalaludeen, A., Peethambaran, P. A., Leo, J. and Manomohan, C. B. 2004. *Duck Production in Kerala.* NATP on Ducks, COVAS, KAU, Mannuthy. 44p.

[8] Khokhlov, R. YU. 2008. Morphology of an Infundibulum of the oviduct of the sexually mature hens. *Int. J. Morphol.* 26(4):883-886.

[9] Khokhlov, R. YU. and Kuznetcov, S. I. 2007. Morphogenesis of a tunica mucosa of oviduct of the hens. *Int. J. Morphol.* 25 (2): 329-333.

[10] King, A. S. 1975. Aves - Urogenital system. In: *Sisson and Grossman's the Anatomy of the Domestic Animals.* Getty, R. (ed.). Vol. 2. Fifth edition. W. B. Saunders Co., Philadelphia pp. 1935-1959.

[11] Lucy, K. M. and Harshan, K. R. 1999. Structure and development of infundibulum in Japanese quail. *Indian J. Poult. Sci.* 34 (2): 125-128.

[12] Luna, L. G. 1968. Manual of Histological Staining Methods of the Armed Forces Institute of Pathology. Third edition. Mc Graw-Hill Book Company, New York, 258p.

[13] Mohammadpour, A. A. and Keshtmandi, M. 2008. Histomorphological study on infundibulum and magnum in turkey and pigeon. *World J. Zool.* 3 (2): 47-50.

[14] Moraes, C., Artoni, S. M. B., Oliveira, D. Pacheco, M. R., Amoroso, L. and Franzo, V. S. 2007. Morphology and morphometry of *Nothura maculosa* quail oviduct. *Ciência Rural, Santa Maria*. 37 (1): 146-152.

[15] Naragude, H. B., Mugale, R. R., Bhosale, N. S. and Gayake, H. P. 1999. Age related changes in the morphology and morphometry of avian oviduct. *Indian J. Vet.* 76: 1115-1116.

[16] Nickel, R., Schummer, A. and Sieferle, E. 1977. *Anatomy of the Domestic Birds*. Verlag Paul Parey, Berlin, 202p.

[17] Ozen, A., Ergun, E. and Kurum, A. 2009. Light and electron microscopic studies on the oviduct epithelium of the Pekin duck (*Anas platyrhynchos*). *Ankara Univ. Vet. Fak. Derg.*, 56: 177-181.

[18] Rao, T. S. C. 1994. Microanatomical studies on the reproductive system of the Domestic Duck (*Anas boschas domesticus*). Doctor of Philosophy in Anatomy. Tamil Nadu Veterinary and Animal Sciences University, Madras. 145p.

AUTHORS

First Author – Patki, H. S., PhD Scholar, Department of Veterinary Anatomy and Histology, College of Veterinary and Animal Sciences, Kerala Veterinary and Animal Sciences University, Mannuthy, Thrissur -680 651, Kerala.
author email: hpatki@gmail.com
Second Author – Lucy, K.M., Associate Professor, Department of Veterinary Anatomy and Histology, College of Veterinary and Animal Sciences, Kerala Veterinary and Animal Sciences University, Mannuthy, Thrissur -680 651, Kerala.
author email: drlucykm@yahoo.co.in
Third Author – Chungath, J. J., Professor, Department of Veterinary Anatomy and Histology, College of Veterinary and Animal Sciences, Kerala Veterinary and Animal Sciences University, Mannuthy, Thrissur -680 651, Kerala.
author email: jjchungath55@gmail.com

Correspondence Author – Patki, H. S., PhD Scholar, Department of Veterinary Anatomy and Histology, College of Veterinary and Animal Sciences, Kerala Veterinary and Animal Sciences University, Mannuthy, Thrissur -680 651, Kerala.
*Corresponding author email: hpatki@gmail.com

Table 1. Different micrometric parameters of the Infundibulum of the oviduct in Kuttanad Duck at 12th, 18th and 24th week of age (In µm as Mean ± S.E.)

Sr. No.	Region of the Infundibulum	At 12th week	At 18th week	At 24th week
1	**Funnel**	**(In µm) Mean ± S.E.**		
	Ciliated Epithelium	14.00 ± 0.10	18.5 ± 0.10	20.13 ± 0.87
	Goblet cell	12.25 ± 0.78	14.00 ± 0.10	19.25 ± 1.11
	Height of mucosal fold	67.50 ± 0.10	135.00 ± 0.00	261.00 ± 5.69
	Width of mucosal fold	81.00 ± 0.10	58.50 ± 2.85	103.50 ± 2.85
	Tunica muscularis	54.00 ± 0.10	108.00 ± 0.10	200.25 ± 2.25
2	**Neck**	**(In µm) Mean ± S.E.**		
	Ciliated Epithelium	14.00 ± 0.01	18.00 ± 0.01	26.83 ± 0.74
	Goblet cell	12.25 ± 0.10	14.00 ± 0.10	28.00 ± 0.00
	Diameter of gland	51.92 ± 0.58	54.83 ± 0.74	70.00 ± 0.03
	Lumen of gland	16.83 ± 0.57	19.83 ± 0.74	35.00 ± 0.10
	Gland cells	17.54 ± 0.04	17.50 ± 0.00	17.50 ± 0.10
	Height of mucosal fold	157.50 ± 2.85	175.50 ± 4.93	618.75 ± 20.74
	Width of mucosal fold	72.00 ± 2.85	85.50 ± 2.85	126.00 ± 2.85
	Tunica Muscularis	67.00 ± 0.01	121.00 ± 0.10	333.00 ± 2.85

Legend to figures

Fig. 1 C. S. of cranial region of the oviduct (day-old). H & E. x 100

1. Epithelium 2. Sub-epithelial connective tissue 3. Mucosal fold

Fig. 2 C. S. of oviduct with ventral ligament (day-old). H & E. x 400

1. Wall of oviduct 2. Ventral ligament with smooth muscles

Fig. 3 C. S. of funnel of infundibulum showing low mucosal folds (12 weeks). H & E. x 400

1. Lamina epithelialis 2. Lamina propria without glands 3. Vessels 4. Tunica muscularis

Fig. 4 C. S. of funnel of infundibulum showing mucosal folds (14 weeks). H & E. x 400

1. Lamina epithelialis 2. Cilia 3. Lamina propria 4. Lymphocytes

Fig. 5 C. S. of infundibular neck (20 weeks). H & E. x100

1. Lamina epithelialis 2. Lamina propria 3. Tunica muscularis 4. Serosa

Fig. 6 C. S. of infundibular neck showing glandular groove (20 weeks). H & E. x 400

1. Lamina epithelialis 2. Glandular groove 3. Lamina propria 4. Tunica muscularis

Fig. 7 C. S. of infundibular neck with tubular glands (24 weeks). H & E. x 400

1. Lamina epithelialis with ciliated cells 2. Lamina propria 3. Gland 4. Tunica muscularis

Fig. 8 C. S. of caudal most region of infundibular neck showing goblet cells (24 weeks). H & E. x 100

1. Lamina epithelialis 2. Tubular glands in lamina propria 3. Goblet cells

Fig. 9 C. S. of infundibular neck showing outer layers (24 weeks). H & E. x 400

1. Tunica muscularis 2. Serosa

Fig.1

Fig.2

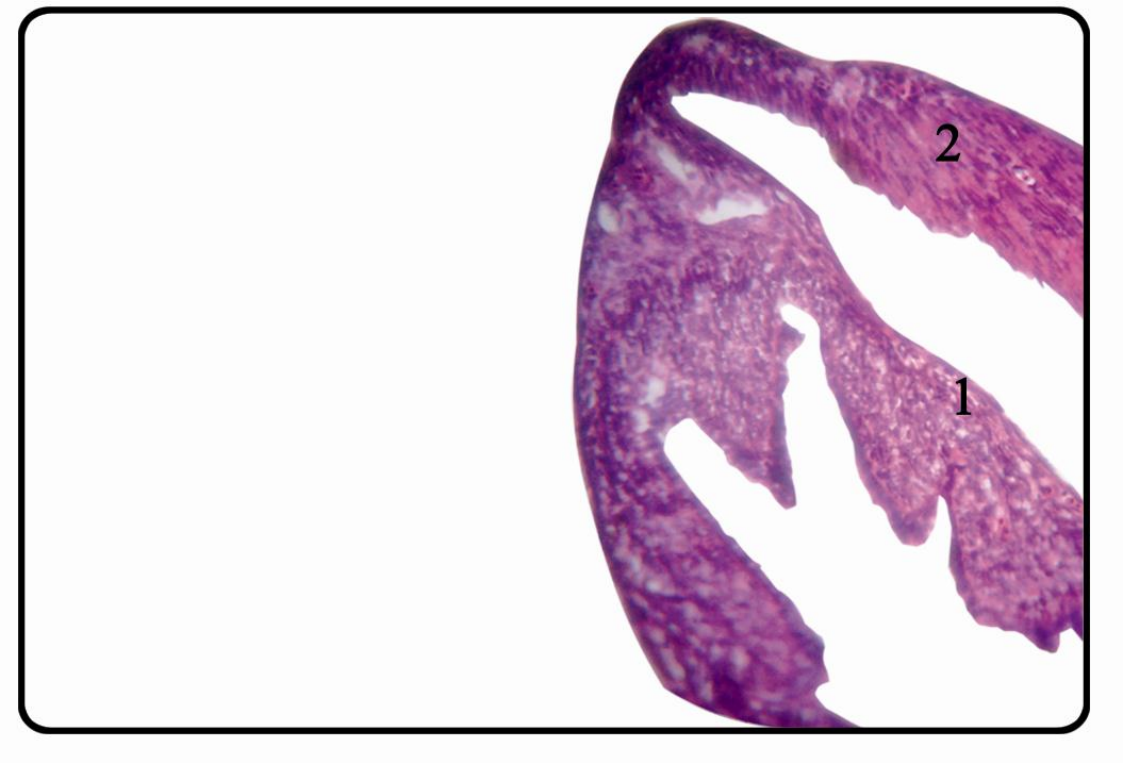

Fig.3

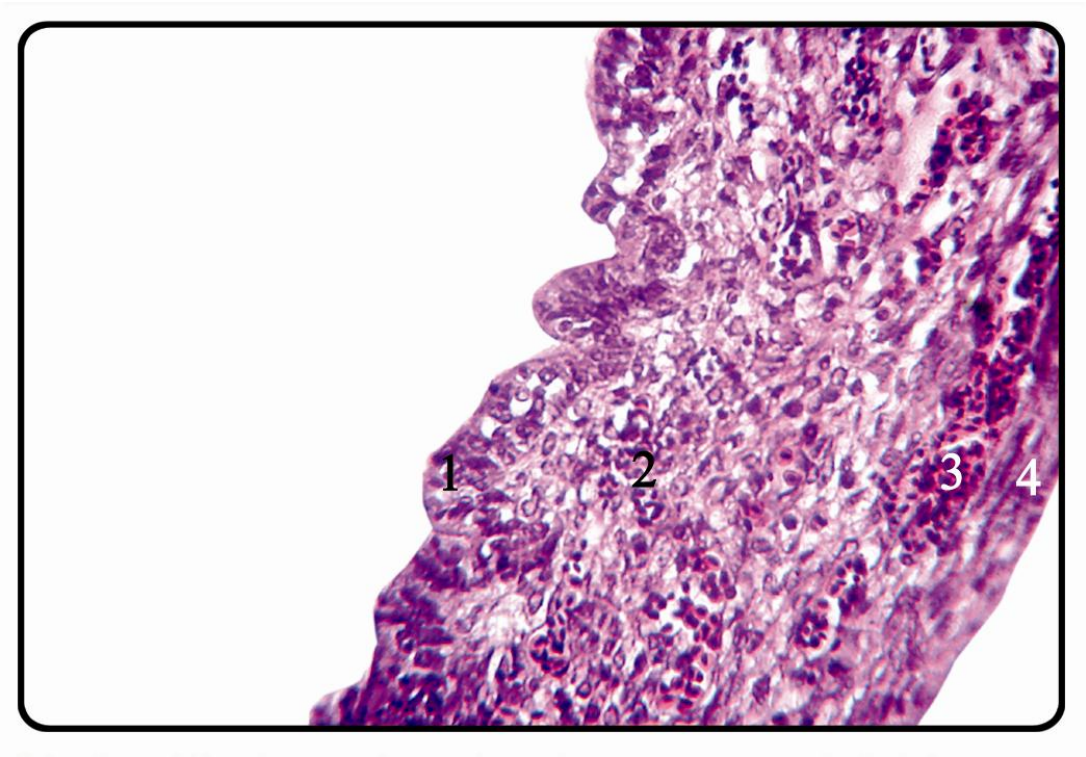

Fig. 4

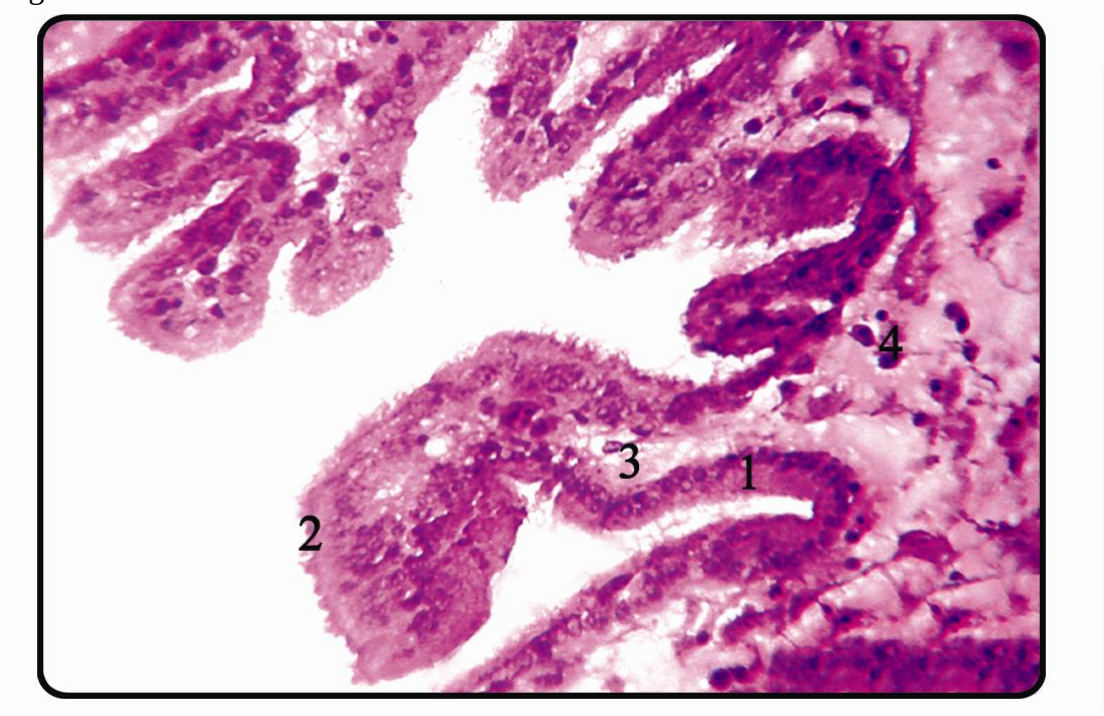

Fig. 5

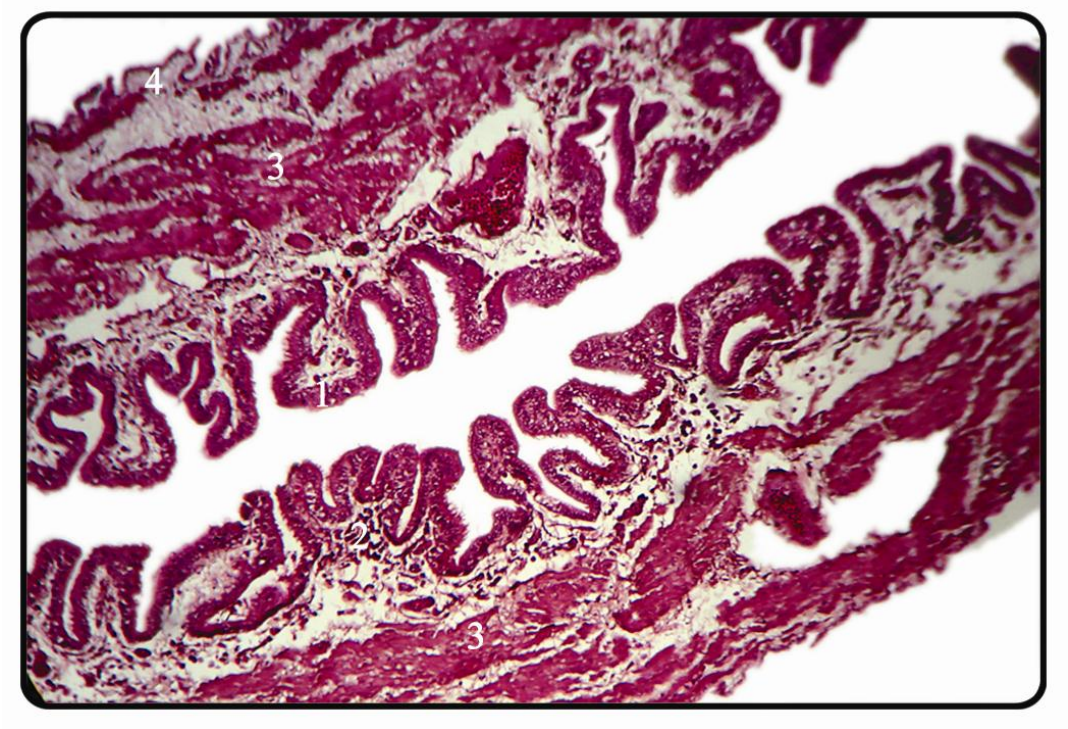

Fig. 6

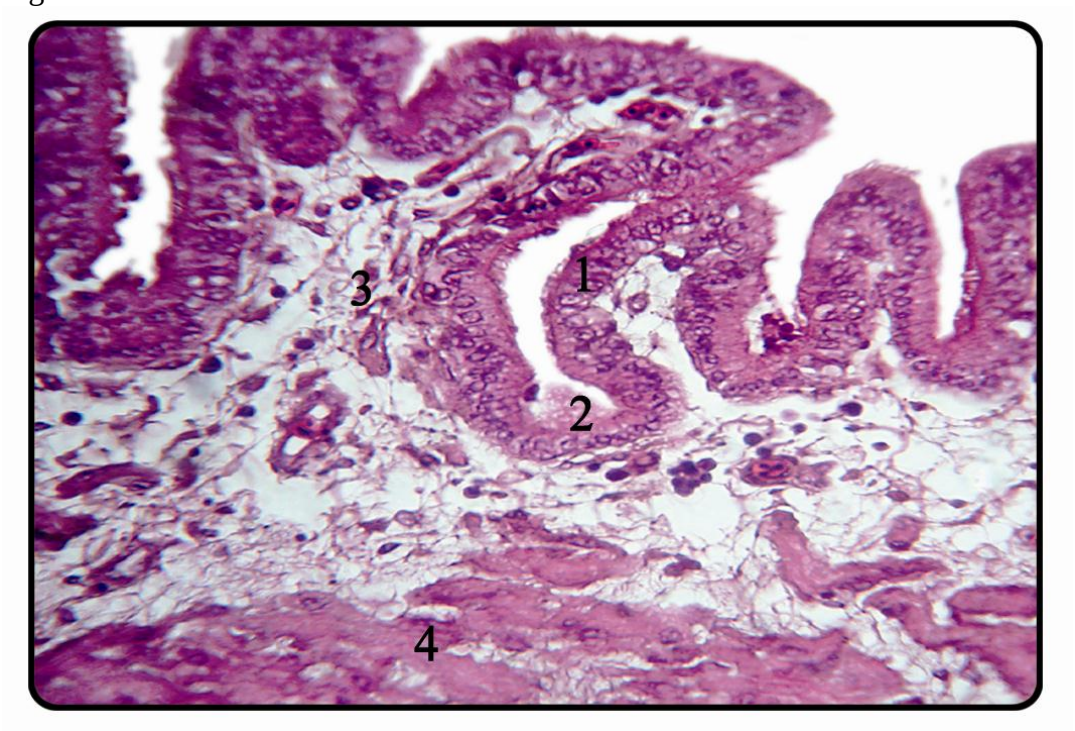

Fig. 7

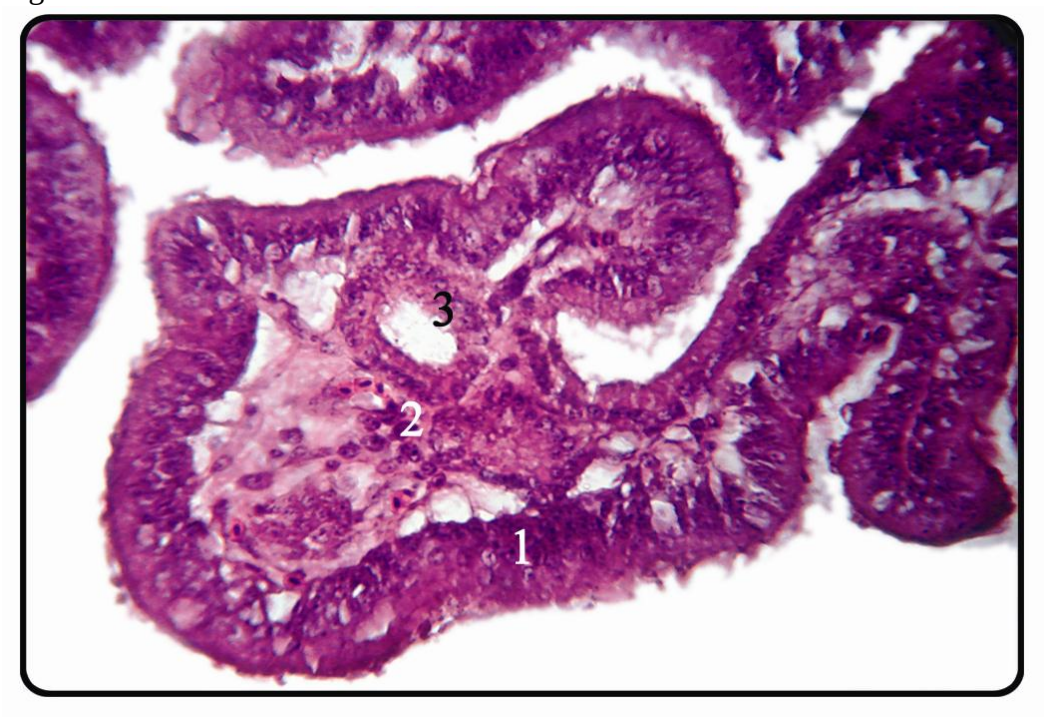

Fig. 8

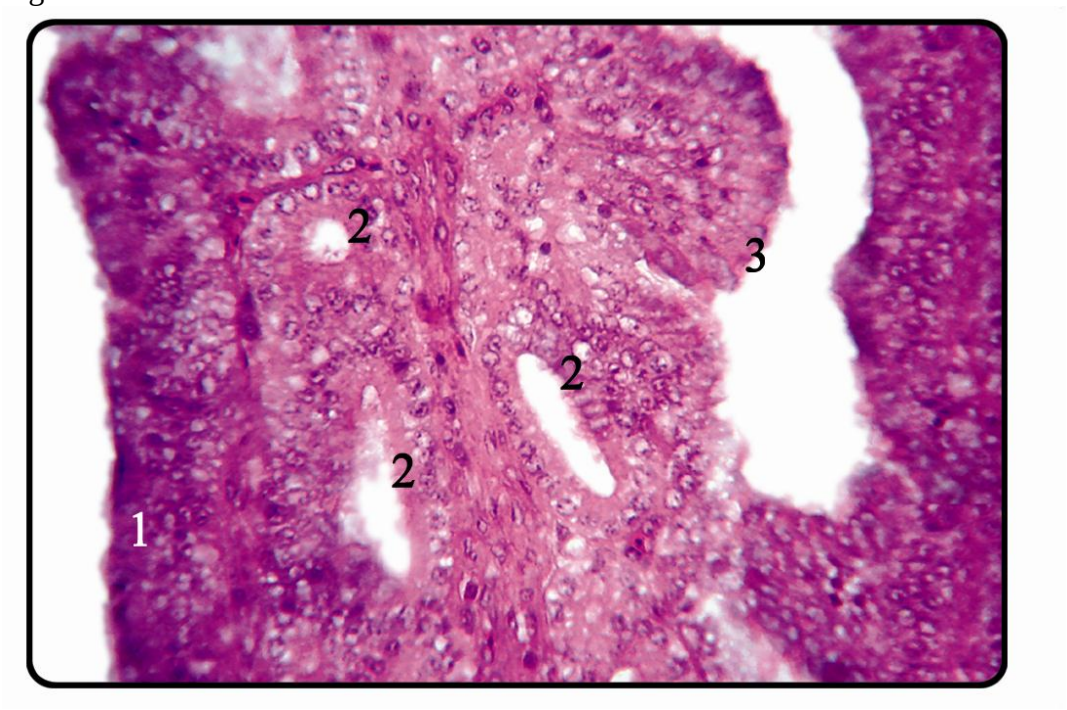

Fig. 9