

Cytological evaluation of thyroid swellings in tribal population of Jharkhand

Shailendra Nath Paul, Anjana Kumari, Saket Kumar.

Department of Pathology,
M.G.M Medical College and Hospital, Jamshedpur (Jharkhand), India.

Abstract- The goal of this study was to evaluate the diagnostic value of FNAC in the diagnosis of the thyroid swellings. Fine needle aspiration cytology is the unique tool for the pre-operative decision-making of the thyroid swellings. This research work was performed at the department of pathology, MGM Medical College and Hospital, Jamshedpur, Jharkhand. This was cross-sectional comparative study. The period of the study was two years from March, 2014 to February, 2016. The study group constituted of 112 patients presenting with thyroid swelling attending a tertiary care centre in MGM Medical College and Hospital, Jamshedpur, Jharkhand. FN aspiration were carried out in all cases and compared with surgical biopsies taking as gold standard. FNAC was done on total of 112 cases of the thyroid swellings. Females outnumbered males with a ratio of 3:1(85females and 27 males). In the FNAC, maximum cases (75.90%) were of colloid goitre, follicular carcinoma was found in 7.14% and anaplastic carcinoma in 3.57% of cases. Microscopical examination of stained tissue sections showed predominantly colloid goitre (72.32%) and then follicular carcinoma (8.04%). The overall incidence of malignancy was 11.61% diagnose by HPE and 9.82% by FNAC. FNAC is a primary diagnostic device for the pre-operative screening of thyroid swellings. It is simple, safe, reliable, minimally invasive, and cost effective.

Keywords – Fine needle aspiration cytology (FNAC), Histopathological examination (HPE), Ultrasonography (USG), Outpatient Department (OPD).

I. INTRODUCTION

Now-a-days different imaging techniques are used for pre operative diagnosis of thyroid swellings but still FNAC is regarded as the single most and cost effective procedure. FNAC of thyroid gland is now a well established, first line diagnostic tool for the evaluation of diffuse thyroid lesion as well as solitary thyroid nodule (STN) with main purpose of confirming benign lesion and by reducing unnecessary surgery. Thyroid nodules associated with troublesome clinical features were considered for FNAC. It should also be performed on nodules with abnormal USG findings. Aspiration is usually performed without local anesthesia and the patient does not require any previous preparation. Although there is a large body of world literature claiming the accuracy and advantages of thyroid aspiration cytology, there is also documents of showing possible limitations and hazards of this procedure. The best outcome of FNAC can be achieved by clinical assessment prior to the procedure, observation made by the performer during the procedure, quality of smear prepared, final microscopy evaluation and reports. The goals and objectives of the study were-

- a) To study the benefit of FNAC as a simple tool for the diagnosis of thyroid swellings.
- b) To compare the pre-operative FNAC with post operative HPE and to determine the sensitivity and specificity of this test.

II. MATERIALS AND METHODS

It was a case-control study organized at the department of pathology, MGM Medical College and Hospital, Jamshedpur, Jharkhand. The duration of study was two years from March, 2014 to February, 2016. This study included 112 subjects of thyroid swelling attending the outpatient department (OPD) of MGM Medical college and Hospital, Jamshedpur and sent them to pathology department for FNAC. The patients of all age groups and both sexes with thyroid swellings, were included in this study.

The principle out-come measures were to correlate the FNAC findings with clinical findings and also with that of postoperative histopathological findings.

A. Procedure of FNAC

The procedure was explained briefly to the patients for their cooperation. FNA of thyroid swelling was less painful, so no local anesthesia was used. First of all the skin over the swelling was cleaned, than it was fixed in between the left thumb and index finger and a disposable plastic 10 ml syringe fitted in to 23 gauge disposable needle was held in the right hand.

The needle was inserted vertical direction with the plunger of the syringe in the resting position. When the needle was in the right position, the plunger was retreated up-to a negative volume of 10 ml. Then the needle was moved back and forth within the lesion in different directions. FNAspiration was stopped if any material was found to appear in the hub of the needle, released the negative pressure before the needle was withdrawn. For each aspiration, 3 to 5 alcohol fixed (wet smear) and air dried smears were prepared. The wet smear was stained with Papanicolaou stain and dried smear was strained with Giemsa (MGG) stain or Leishman stain. A smear was considered satisfactory if it contained at-least 5 to 6 groups of 10 -15 well preserved follicular cells.

Finally, accuracy, sensitivity, specificity, etc were calculated by using standard criteria.

B. Statistical Analysis Used

The investigated data was thoroughly cleaned and entered into MS-Excel spread sheets and analyzed. Percentage were used in this study to analyze epidemiological variables

Accuracy: $((TP + TN) * 100) \div (TP + TN + FP + FN) = 99.11\%$

Specificity: $(TN * 100) \div (TN + FP) = 100\%$

Sensitivity: $(TP * 100) \div (TP + FN) = 91.67\%$

False Positive: $(FP * 100) \div (FP + TN) = 0\%$

False Negative: $(FN * 100) \div (FN + TP) = 8.33\%$

Predictive Value of a Positive Test : $(TP * 100) \div (TP + FP) = 100\%$

Predictive Value of a Negative Test : $(TN * 100) \div (TN + FN) = 99.01\%$

III. RESULTS

The research incorporated 112 cases of thyroid swellings. The female and male ratio was of 3:1 which is shown in fig 1.

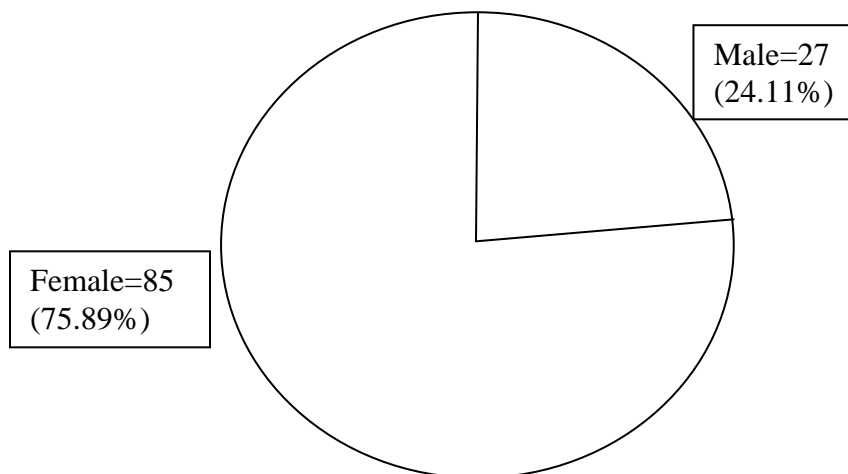


Fig 1. Gender wise distribution of studied patients.

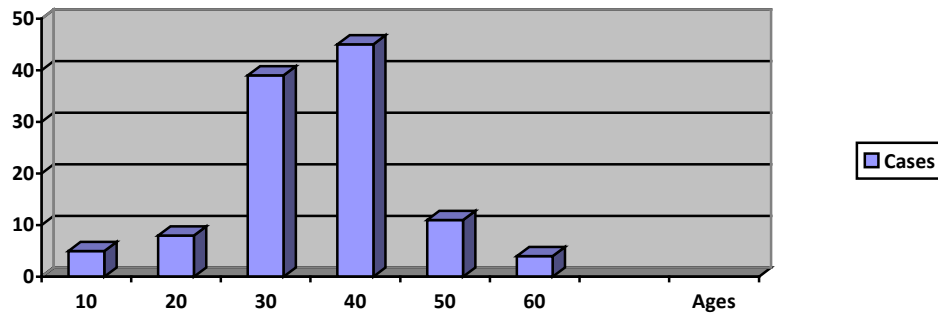


Fig. 2: Age wise distribution of studied population.

Maximum cases belonged to the age group of 21-40 years. Most of the patients presented in fourth decade (40.18%) followed by third decade (34.82%) shown in fig 2.

In this study FNAC was done in all 112 cases on an OPD basis. The greater number of the cases (75.90%) were diagnosed as colloid goitre. Follicular carcinoma was detected in 7.14% and anaplastic carcinoma in 3.57% of cases. Excisional biopsy and HPE were done in all the cases of thyroid swellings. In my research work, HPE showed 72.32% were of colloid goitre and 8.04% were of follicular carcinoma (table – 1).

Table 1. Thyroid swelling diagnosed by FNAC and HPE.

Diagnosis of Thyroid Swelling	Test	No. of Cases	Percentage
Colloid goitre	FNAC	85	75.90
	HPE	81	72.32
Granulomatous Thyroiditis	FNAC	08	7.14
	HPE	09	8.04
Follicular adenoma	FNAC	07	6.25
	HPE	08	7.14
Follicular carcinoma	FNAC	08	7.14
	HPE	09	8.04
Anaplastic carcinoma	FNAC	04	3.57
	HPE	05	4.46
Total	FNAC	112	100
	HPE	112	100

The overall prevalence of malignancy was 11.61 percent by HPE and 9.82 percent by FNAC. By FNAC 9.41 percent and by HPE 10.9 percent cases were diagnosed as malignant among females whereas among males 14.81 percent cases were malignant as per FNAC and 18.52 percent were malignant as per HPE. In our research, the malignant rate was more in men (18.52%) as compared to women (10.59%) as shown in (table-2).

Table 2. Sex distribution of prevalence of malignancy as per FNAC and HPE.

Sex	Test	Total	Benign (%)	Malignant (%)
Female	FNAC	85	77 (90.59)	08 (9.41)
	HPE		76 (89.41)	09 (10.59)
Male	FNAC	27	23 (85.19)	04 (14.81)
	HPE		22 (81.48)	05 (18.52)
Total	FNAC	112	101 (90.18)	11 (9.82)
	HPE		99 (88.39)	13 (11.61)

The diagnostic value in FNAC in our research was that 11 cases were true positive while 100 cases were true negative. In thesis false positive cases were zero while false negative cases were one [Table-3]

True positive (TP) cases are those which are diagnosed correctly as malignant and true negative (TN) are those which are diagnosed correctly as benign. False positive (FP) cases are those which are benign but wrongly diagnosed as malignant. False negative (FN) are those cases which are malignant but are diagnosed as benign.

According to the research data of FNAC, the accuracy was 99.11 percent while sensitivity was 91.67 percent and specificity was 100 percent. PPV and NPV was 100 percent and 99.01 percent respectively.

Table 3. Correlation of FNAC and HPE in detecting the malignant nature of thyroid swelling.

FNAC diagnosis	Histopathological diagnosis		
	Malignant	Benign	Total
Positive	11 (TP)	0 (FP)	11
Negative	1 (FN)	100 (TN)	101
Total	12	100	112

IV. DISCUSSION

FNAC is an accurate preoperative screening method for the detection of thyroid lesions and distinguishing between benign and malignant lesions. Majority of clinically diagnosed thyroid nodules are non-neoplastic, only 5% -30% are neoplastic and require surgical intervention. We had a diagnostic accuracy of 99.11 percent with a predictive value for negative test of 99.01 percent. Overall of current research confirms the predictive value of FNAC as diagnostic tool.

In this thesis papillary carcinoma was not found. Most of the patients presented thyroid swellings in fourth and third decades of life which is also in accordance to the study of Bukhari and colleagues. The accuracy, percentage of false positive, and predictive value for negative result of FNAC as reported by the workers in this field as shown in table 4 and 5.

In our series, HPE showed a malignancy rate of 11.61 percent (13 cases out of 112 cases). The specificity was 100 percent, the sensitivity was 91.67 percent as compared with 64.3 percent sensitivity reported by others.

Table 4. Comparison of the results of this study with other reported.

Authors	Accuracy (%)	Sensitivity (%)	Specificity (%)	PPV (%)	NPV (%)
Ko et al 2003	84.4	78.4	98.2	99.0	66.3
Morgan et al 2003	67.2	55.0	73.7	70.0	67.4
Jogal et al 2005	78.1	88.4	99.1	---	---
Cal et al 2006	97.0	83.3	98.0	71.4	98.4
This study 2016	99.11	91.67	100	100	99.01

PPV:- Positive predictive value, NPV:- Negative predictive value

Table 5. Percentage incidence of malignancy as reported.

Authors	Year	Incidence (%)
Kapur et al.	1982	11
Bhansali	1982	9
Ng Eh et al.	1992	18.4-26.2
Adwork J. A.	1995	15
Abu Eshy et al.	1995	15.2

The follicular variant of papillary carcinoma is a hazard in thyroid FNAC. FNA smears show hypercellularity with a prominent follicular pattern but no obvious papillae. Leung et al disclosed that true nature of the histological variants of the papillary carcinoma cannot be foretold from the appearance of the FNAC.

Agarwal et al evaluated thyroid nodules in 100 cases, FNAC displayed an accuracy of 19.9 percent, sensitivity of 76.5 percent, and a specificity of 99.5 percent. False positive 2 percent, false negative 4 percent, PPV and NPV was 86.7 percent and 92.2 percent. They recapitulated FNAC as an accessory to clinical judgment not to replace it. In 1995, Ghosal, Pal, Mazumdar reported that accuracy rate of FNAC was 93 percent.

FNAC is common investigation in the diagnosis of superficial lumps though it's success depends on the skill of the person performing the procedure. The major drawback of FNAC is the lack of reliability with respect to distinguishing follicular adenoma from follicular carcinoma. The reason for this is that diagnosis of each entity is based on histological criteria i.e. vascular &/or capsular invasion. FNAC cannot provide this information.

V. CONCLUSION

FNAC is a primary diagnostic tool for thyroid nodules because it's one of the most useful, simple, safe, quick, reliable, minimally invasive, and cost effective. It can differentiate non-neoplastic lesions from neoplastic lesions and can be performed in OPD. It is easily reputable and is highly patient-compliant. FNAC is not a substitute for HPE.

REFERENCES

- [1] Frable WJ. Thin-needle aspiration biopsy. A personal experience with 469 cases. *Am J Clin Path.* 1976;65:168-82.[PubMed:56129]
- [2] Gershengorn MG, McLung MR, Chu EW, Hanson TA, Weintrub BD, Robins J. Fine-needle aspiration cytology in the preoperative diagnosis of thyroid nodules. *Ann Intern Med.* 1977;87:265-9. [PubMed:900668]
- [3] Rosen IB, Wallace C, Strawbridge HG, Walfish PG. Re-evaluation of needle aspiration cytology in detection of thyroid cancer. *Surgery.* 1981;90:747-56 [PubMed: 7281013]
- [4] Schlesinger MJ, Gargill SL, Saxe IH. Studies in nodular goiter: Incidence of thyroid nodules in routine necropsies in nongoitrous region. *JAMA.* 1938;110:1638.
- [5] Kendall LW, Condon RE. Prediction of malignancy in solitary thyroid nodules. *Lancet.* 1969;1:1071-3.
- [6] Kapur MM, Sarin R, Karmakar MG, Sarda AK. Solitary thyroid nodule. *Ind J Surg.* 1982;44:174-9.
- [7] Bhansali SK. Solitary nodule in the thyroid gland: experience with 600 cases. *Ind J Surg.* 1982;44:547-61.
- [8] Nguyen TD, Chassard JL, Lagarde P. Results of postoperative radiation therapy. A retrospective study. *The Radiotherapy Cooperative Group. Radiother Oncol.* 1992;23:1-5.
- [9] Adwok JA. Treatment of thyroid cancer. *East Afr Med J.* 1994;71:524-6.
- [10] Abu-Eshy SA, Khan AR, Khan GM, al-Humaidi MA, al-Shehri MY, Malatani TS. Thyroid malignancy in multinodular goitre and solitary nodule. *J R Coll Surg Edinb.* 1995;40:310-2.
- [11] Rajatanavin R, Chailurkit LO, Tirarungsikul K, Chalayondeja W. 1990 Postpartum thyroid dysfunction in Bangkok: Ageographical variation in the prevalence. *Acta Endocrinol* 1990;122:283-7.
- [12] Agarwal A, Mishra SK. Completion total thyroidectomy in the management of differentiated thyroid carcinoma. *Aust N Z J Surg.* 1996;66:358-60.
- [13] Ghosal B, Pal NC, Majumder P. FNAC of Thyroid gland. *Ind J Surg.* 1980;146:76-83.
- [14] Gardner HA, Ducatman BS, Wang HH. Predictive value of FNA of the thyroid in classification of follicular lesions. *Cancer.* 1993;71:2598-603.
- [15] Reagon LR, Farkas T, Dehner LP. FNAC of the thyroid: a cytologic correlation and study of discrete cases. *Thyroid* 2004;14:35-41.
- [16] Sadler TW. Head and neck. In: Sadler TW, editor. *Langman medical embryology.* Tenth ed. New York: Lippincott Williams Wilkins, 2006:257-64.
- [17] Saddique M, Islam UU, Iqbal P, Baloch QU. FNAC: A reliable diagnostic tool in solitary thyroid nodule and multinodular goitre. *Pak J Surg.* 2008;24:188-191.
- [18] Gharib H, Goellner JR. FNA biopsy of the thyroid: an appraisal. *Ann Intern Med* 1993;118:282-9.
- [19] Sclabas GM, Shapiro SE, et al. FNA of the thyroid and correlation with histopathology in a contemporary series of 240 patients. *Am J Surg* 2003;186:702-10.
- [20] Goellner JK, Gharib H, Grant CS, Johnson DA. FNAC of the thyroid, 1980 to 1996. *Acta Cytol* 1987;31:587-90.
- [21] Galen RS, Gambino SR. *Beyond normality: the predictive value and efficiency of medical diagnosis.* New York: John Wiley, 1975:9-14.
- [22] Cai XJ, Nixon P, Waghorn AG, Giles T. Ultrasound-guided FNAC in the diagnosis and management of thyroid nodules. *Cytopathology* 2006;17:251-6.

AUTHORS

First Author – Shailendra Nath Paul, M.D (Pathology), Associate Professor Deptt. Of Pathology, MGM Medical College Jamshedpur, Jharkhand, shailendra.paul61@gmail.com

Second Author – Anjana Kumari, M.D (Pathology), Assistant Professor Deptt. Of Pathology, MGM Medical College Jamshedpur, Jharkhand, dranjanalal@gmail.com

Third Author – Saket Kumar, M.D (Pathology), Assistant Professor Deptt. Of Pathology, MGM Medical College Jamshedpur, Jharkhand, krsaket84@gmail.com

Correspondence Author – Shailendra Nath Paul, shailendra.paul61@gmail.com, 9934399362.