

# Pure Neuritic Leprosy: A Rare Case Report

Yogesh Tayade, N.V.Dravid, K.H.Suryawanshi, Sushil Mahajan, Rajeshwari K

Department of Pathology, JMF's ACPM Medical College, Dhule, Maharashtra, India

**Abstract-** Leprosy is one of the most common diseases of peripheral nerves. Pure neuritic leprosy constitutes about 4-10 % of all leprosy cases, clinically limited to the peripheral nerves without skin changes. Diagnosis of leprosy in absence of typical dermatological features is difficult and requires histopathological confirmation using nerve biopsy.

We report a case of leprosy without skin lesions. Nerve biopsy showed chronic inflammatory cell infiltration, epithelioid cell granulomas and presence of mycobacterium leprae on Modified Ziehl Neelson stain. Hence in leprosy prevalent countries like India, this form of leprosy should be thoroughly investigated especially in patient without skin changes.

**INDEX TERMS-** NEURITIC LEPROSY, NERVE BIOPSY, LEPROSY NEUROPATHY

## I. INTRODUCTION

Leprosy is one of the common treatable dermato-neurologic disease affecting skin and peripheral nerves. Prevalence of disease is decreasing; still leprosy represents one of the major public health problems mainly in India and Brazil.<sup>1-3</sup> Diagnosis of leprosy is straight forward when both cutaneous and neurological involvements are present together. Patient with leprosy may have only nerve involvement without obvious primary skin lesions is called pure neuritic leprosy.<sup>4,6</sup> Patient with "pure neuritic" form of leprosy are frequently misdiagnosed because of absence of skin lesions.<sup>7</sup> We report a case of unusual presentation of Polyneuritic Leprosy diagnosed on histopathology of nerve biopsy.

## II. CASE REPORT

A 33 years old male presented with complaints of decreasing sensations of both lower limbs and right upper limb since one year and trophic ulcers on fingers and toes since five months [figure-1]. Patient was nondiabetic and nonalcoholic. There was no history of skin lesions or contact with person suffering from leprosy.

On general examination patient revealed mild pallor and was afebrile. Trophic ulcers were present on fingers and toes. Examination of skin did not reveal any skin lesions suggestive of leprosy.

On CNS examination, patient was conscious & well oriented. Reflexes were decreased in right upper limb and were absent in both lower limbs. On examination for sensory function, there was distal stocking and glove distribution on right upper limb and both lower limbs with thermal and pinprick anesthesia and preservation of proprioception. Both planter reflexes were flexor. Other systemic examination did not reveal any abnormality. Laboratory investigations revealed hypochromic

microcytic anemia. Blood sugar, liver & renal function tests were within normal limits. Serology showed VDRL & HIV nonreactive, X ray chest was normal. Nerve conduction velocity study was abnormal suggestive of generalized mixed (axonal & demyelinating) sensory-motor peripheral neuropathy. Clinical suspicion was mixed sensory-motor peripheral neuropathy ?vasculitic, ?autoimmune origin.

For confirmation of peripheral neuropathy, Sural nerve biopsy was performed.

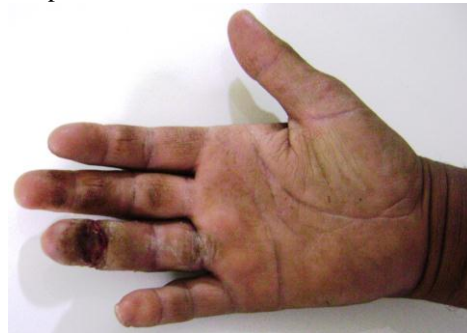

Figure 1: Clinical photograph showing trophic ulcers on fingers.

**Microscopy:** Histopathological examination showed intense lymphocytic infiltration predominantly in endoneurium and perineurium along with few ill formed granulomas and plasma cells. Perineurium showed thickening & fibrosis at places. Perivascular lymphocytic infiltration was absent. Special stain-Modified Ziehl Neelson stain showed few acid fast bacilli(+), Toluidine blue – showed focal areas of demyelination. Modified Ziehl Neelson stain of smears from finger ulcers were negative for AFB. The diagnosis of pure neuritic leprosy was made. (Figures 2,3,4)

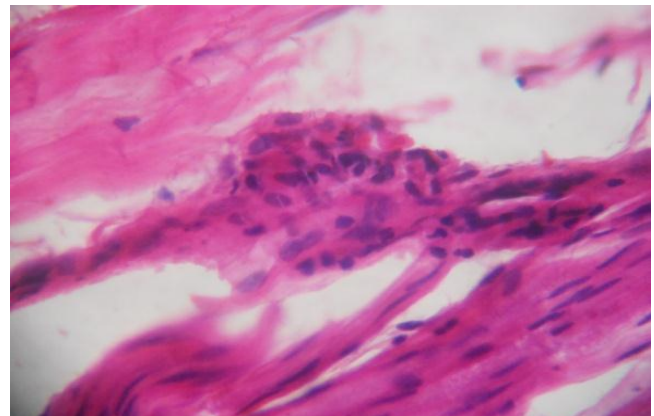


Figure 2: Epithelioid granuloma with nerve. (H & E ,40X)

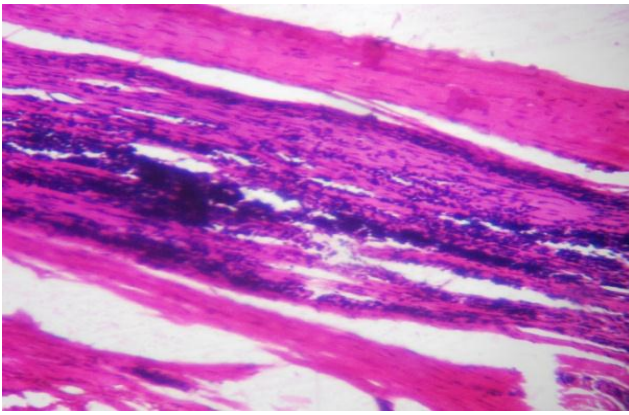


Figure 3: Intense lymphocytic infiltrate in endoneurium and perineurium. (H & E ,10X)



Figure 4: Modified ZN stain showing AFB (+).

### III. Discussion

Pure neuritic leprosy is rare and distinct subtype frequently seen in tropical countries like India. It is an uncommon presentation in a leprosy patient. Neural leprosy is difficult to diagnose in absence of skin lesions and needs histological confirmation<sup>8</sup>. Peripheral nerve enlargement is not consistently present. In this patient pure polyneuritic form of leprosy was histopathologically diagnosed. Clinical suspicion was mixed sensory-motor peripheral neuropathy? vasculitic, ?autoimmune, Leprosy was not clinically suspected.

We report this case because it presented with unusual manifestation. This form of leprosy is still active in India and its diagnosis is usually missed.<sup>9</sup> Peripheral nerve biopsy is one of the best procedures for patients with small fiber neuropathy without skin lesions. There is need to pay more attention to this form of leprosy to diagnose and treat patients earlier and to prevent sequelae. In conclusion, unusual presentation of leprosy should be clinically suspected as pure neuritic leprosy. It should be considered as one of the differential diagnoses of peripheral neuropathy and thoroughly investigated with nerve biopsy followed by histopathological examination.

### REFERENCES

1] Noorden SK. Elimination of leprosy as a public health problem: progress and prospects. Bull WHO 1995;73:1-6.

- 2] Talwar S, Jha PK, Tiwari VD. Neuritic leprosy: epidemiology and therapeutic responsiveness. Lepr Rev 1992;63:263-268.
- 3] Andrade V, Militão de Albuquerque MD, Chagastelles Sabroza P. The importance of operational factors for the interpretation of indicators in the Hansen's disease endemic in Brazil. Acta Leprol 1997;10:131-139.
- 4] Girdhar BK. Neuritic leprosy. Indian J Lepr 1996;68:35-42.
- 5] Jennekens FGI, van Brakel WH. Neuropathy in leprosy In Latov N, Wokke JHJ, Kelly JJ Jr (eds). Immunological and infectious disease of peripheral nerves. Cambridge: Cambridge Univ Press, 1998;319-339.
- 6] Mahajan PM, Jogaikar DG, Mehta JM. A study of pure neuritic leprosy: clinical experience. Indian J Lepre 1996;68:137-41.
- 7] van Brakel WH, Khawas IB. Silent neuropathy in leprosy: an epidemiological description. Lepr Rev 1994;65:350-360.
- 8] Vijaikumar M, D'Souza M, Kumar S, Badhe B. Fine needle aspiration cytology (FNAC) of nerves in leprosy. Lepr Rev 2001;72:171-8.
- 9] Gadoth N, Bechar M, Kushnir M, Davidovitz S, Sandbank U. Somatosensory and autonomic neuropathy as the only manifestation of long standing leprosy. J Neurol Sci 1979;43:471-477.

### AUTHORS

**First Author**– Dr. Yogesh Tayade, Assistant Lecturer, Department of Pathology, JMF's ACPM Medical College, Dhule. Email dr.dew.169@gmail.com

**Second Author**- Dr. N. V. Dravid, MD Pathology and Bacteriology, Professor and Head, Department of Pathology, JMF's ACPM Medical College, Dhule

**Third Author** – Dr. K.H. Suryawanshi, Assistant Professor, Department of Pathology, JMF's ACPM Medical College, Dhule

**Fourth Author** – Dr. Sushil Mahajan, MD[Med], DNB[Neuro] Consulting Neurophysician, Dhule.

**Fifth Author** – Dr. Rajeshwari K, Assistant Lecturer, Department of Pathology, JMF's ACPM Medical College, Dhule.

**Correspondence Author** – Dr. Yogesh Tayade.  
Assistant Lecturer,  
Department of Pathology, JMF's ACPM  
Medical College, Dhule  
Email: dr.dew.169@gmail.com  
**Mobile: +91 8698083939**